



Peers Alley Media

1126 59 Ave East, V5X 1Y9

Vancouver BC, Canada

 WhatsApp No: +1 873-889-8976



VIRTUAL EVENT

3rd Global

OPHTHALMOLOGY & EYE DISEASES SUMMIT

NOVEL OPHTHALMOLOGY 2022

<https://novel-ophthalmology.peersalleyconferences.com/>



YOUR FIRST CHOICE FOR RESEARCH INGENUITY

PROGRAM-AT-A-GLANCE

NOVEL OPHTHALMOLOGY
2022

DAY 1

SEPTEMBER 12, 2022

Scientific Program

British Summer Time (BST)

Opening Ceremony @ 08:45 - 09:00

Distinguished Speaker Talks

Sessions: Clinical Ophthalmology | Cataract | Diabetic Retinopathy | Cornea | External Eye Disease | Eye Anatomy | Eye Infections and Allergies | Glaucoma | Lens Disorder | Nano Ophthalmology | Neuro-Ophthalmology | Ocular Inflammation | Retinal Cell Biology | Ophthalmology Surgery | Ocular Inflammation

Session I - 09:00-11:00

09:00-09:20

Title: Combined VEGF/FGF digitized expression analysis on pterygia cell spot arrays

S. Mastronikolis, *University of Patras School of Medicine, Greece*

09:20-09:40

Title: Allocation scheduling leads to optimum utilization of operation theater time

Meeta Tyagi, *Ex. All India Institute of Medical Sciences, India*

09:40-10:00

Title: Identifying diabetes from conjunctival images using a novel hierarchical multi-task network

Xinyue Li, *Shanghai Jiaotong University, China*

10:00-10:20

Title: Cognitive AI for real time prognosis of multimodal genomic and ophthalmic impairments

Ajakwe Simeon Okechukwu, *Kumoh National Institute of Technology, South Korea*

10:20-10:40

Title: Efficacy of honey-based eye drop to relieve ocular signs and symptoms in dry eye: A systematic review

D. Permatasari, *Cipto Mangunkusumo Hospital Kirana, Indonesia*

10:40-11:00

Title: Diabetes retinopathy detection using deep learning
Samira Lafraxo, *Ibn Zohr University, Morocco*

Refreshment Break 11:00-11:15

Session II - 11:15-13:35

11:15-11:35

Title: Late presentation of a patient with a traumatic subconjunctival crystalline lens dislocation
Murat Okutucu, *Recep Tayyip Erdoğan University, Turkey*

11:35-11:55

Title: Impact of cisplatin administration on cerebellar cortical structure and locomotor activity of infantile and juvenile albino rats: The role of oxidative stress
Mohey A.E. Hulail, *Zagazig University, Egypt*

11:55-12:15

Title: Single nucleotide polymorphism of receptor for advanced glycation end- products [rage] gene: Is it a new opening in the risk assessment of diabetic retinopathy?
Pragya Ahuja, *Aligarh Muslim University, India*

12:15-12:35

Title: Acute angle-closure glaucoma after total knee replacement surgery: A Case report
Omar tarkaouchi, *Habib Bourguiba Hospital, Tunisia*

12:35-12:55

Title: Coexistence of posterior polar annular and hemispheric choroidal dystrophy: A case report
Murat Okutucu, *Recep Tayyip Erdoğan University, Turkey*

12:55-13:15

Title: Awareness and attitudes of art students and lecturers on health hazards associated with fine and applied arts making in Nigeria
Christopher Ifeanyi Ibenegbu, *University of Nigeria, Nigeria*

13:15-13:35

Title: Covid-19 pandemic and risk of myopia
Rozhan Khezri, *Iran University of Medical Sciences, Iran*

Lunch Break 13:35-14:20

Session III - 14:20-16:20

14:20-14:40

Title: Investigating the mechanisms behind the development of acquired resistance to Anti-VEGF therapy in neovascular diabetic eye disease
Dhyana Sharma, *Medicines and Healthcare Products Regulatory Agency, UK*

14:40-15:00

Title: Epigenetic changes in the promoter of the fragile histidine triad (FHIT) gene in human sebocytes under the influence of *in vitro* culture
Magdalena Jotzo, *Martin-Luther-University Halle-Wittenberg, Germany*

15:00-15:20

Title: Myasthenia gravis in patients treated with immune checkpoint inhibitors
Y. Shames, *Memorial Sloan Kettering Cancer Center, USA*

15:20-15:40

Title: Electrophysiological analysis of traumatic optic neuropathy and traumatic brain injury among active military
Brandon Lucke-Wold, *University of Florida, USA*

15:40 - 16:00

Title: Predominantly practiced leadership styles of chief nursing officers in healthcare organizations
Haroon Malak, *Drexel University, USA*

16:00-16:20

Title: Experiencing a Genetic Disease: Receiving and Transmitting
Catarina Seidi, *University of Aveiro, Portugal*

Panel Discussion

End of Day 1



DAY 2

SEPTEMBER 13, 2022

Scientific Program

British Summer Time (BST)

Distinguished Speaker Talks

Sessions: Clinical Ophthalmology | Cataract | Diabetic Retinopathy | Cornea | External Eye Disease | Eye Anatomy | Eye Infections and Allergies | Glaucoma | Lens Disorder | Nano Ophthalmology | Neuro-Ophthalmology | Ocular Inflammation | Retinal Cell Biology | Ophthalmology Surgery | Ocular Inflammation

Session I - 08:40-11:00

08:40-09:00

Title: Ocular Syphilis

Zaira Fernanda Martinho Nicolau, *Federal University of São Paulo, Brazil*

09:00-09:20

Title: The effect of corneal epithelial redistribution difference on axial length elongation in myopic children with overnight orthokeratology

Yanhua Wang, *Aier Eye Hospital Group, China*

09:20-09:40

Title: Subconjunctival foreign body with suspected scleral penetration

Suwarna Suman, *All India Institute of Medical Sciences Jodhpur, India*

09:40-10:00

Title: Eye disorders spectrum: A tertiary hospital pediatric ophthalmology clinic based in Ethiopia

Yohannes Tewolde Kidane, *Addis Ababa University, Ethiopia*

10:00-10:20

Title: Error-free and mean value based reversible data hiding using gravitational search algorithm in encrypted images

N. Amutha Prabha, *VIT University, India*

10:20-10:40

Title: Visual impairment and its predictors among people living with type 2 diabetes mellitus at Dessie town hospitals, Northeast Ethiopia: Institution-based cross-sectional study

Mohammed Abdu Seid, *Debre Tabor University, Ethiopia*

10:40-11:00

Title: Inadvertent intralenticular Ozurdex removal

Madhurima Roy, *Susrut Eye Foundation and Research Centre, India*

Refreshment Break 11:00-11:15

Session II - 11:15-13:15

11:15-11:35

Title: A rare combination of complication of ruptured aneurysm of the subclinoid portion of the internal carotid artery: Case
Zineb Boukhal Zerouali, *Ibn Rochd University, Morocco*

11:35-11:55

Title: Analysis on the correlation between long-term refractive regression and visual quality after FS-LASIK
Mingyue Zhang, *Civil Aviation Medical Center, China*

11:55-12:15

Title: Feature preserving mesh simplification through anisotropic nyquist based adaptive sampling of points inside the segmented regions
Lida Asgharian, *Sahand University of Technology, Iran*

12:15-12:35

Title: Fixational eyes movements: Hopf bundle, listing's law, and a model of saccadic cycle
D.V. Alekseevsky, *Shiraz University of Medical Sciences, Iran*

12:35-12:55

Title: Improvement of eye dosimetry: The application of photon beam radiotherapy in patients with eye melanoma
M. Živković, *University of Kragujevac, Serbia*

12:55-13:15

Title: Microvascular complications and its predictors among type 2 diabetes mellitus patients at Dessie town Hospitals, Ethiopia
Mohammed Abdu Seid, *Debre Tabor University, Ethiopia*

Lunch Break 13:15-14:00

Session III - 14:00 - 15:00

14:00-14:20

Title: Combat-related ocular injuries in the Israel defense forces during the years 2013 to 2019
N. Shakarchy-Kaminsky, *Israel Defense Forces Medical Corps, Israel*

14:20-14:40

Title: Impact of visual field loss post-stroke on activities of daily living: A prospective cohort study
Christian Garcia, *Tallaght University Hospital, Ireland*

14:40-15:00

Title: Association between body mass index and visual acuity in 1.6 million israeli adolescents
N. Shakarchy-Kaminsky, *Israel Defense Forces Medical Corps, Israel*

Panel Discussion

Closing Remarks



SCIENTIFIC ABSTRACTS

DAY 1



Virtual Event

3RD GLOBAL

Ophthalmology and Eye Diseases Summit

September 12-13, 2022

NOVEL OPHTHALMOLOGY 2022



Combined VEGF/FGF digitized expression analysis on pterygia cell spot arrays

S. Mastronikolis¹, K. Kagkellaris¹, M. Pagkalou²,
E. Tsiambas³, P. Plotas⁴, O.E. Makri¹ and
C.D. Georgakopoulos¹

¹Department of Ophthalmology, University of Patras School of Medicine, Greece

²Department of Chemistry, University of Crete, Greece

³Department of Cytology, 417 VA Hospital (NIMTS), Greece

⁴Laboratory of Primary Health Care, University of Patras, Greece

Objectives: Dysregulation of critical genes implicated in cell proliferation; apoptosis, signal transduction to the nucleus and also angiogenesis are involved in the development and progression of pterygia. Among them, growth factors including vascular endothelial growth factor (VEGF) and fibroblastic growth factor (FGF) affect significantly the fibrovascular micro-environment inducing neo-angiogenic activity.

Scope: To co-analyze VEGF/FGF protein expression patterns in a series of pterygia based on a combination of sophisticated techniques.

Methods: Using a liquid-based cytology assay, thirty (n = 30) cell specimens were obtained by applying a smooth scraping on conjunctiva epithelia and fixed accordingly. Similarly, the same process was applied also in normal conjunctiva epithelia (n = 10; control group). We constructed five (n = 5) slides each containing eight (n = 8) cell spots. An immunocytochemistry (ICC) assay was implemented for both molecules. Digital image analysis was also performed for evaluating objectively the corresponding immunostaining intensity levels. Chi-Square and Fisher exact

tests were implemented considering $p < 0,05$ (two tailed) values statistically significant.

Results: All the examined pterygia cell samples over-expressed the marker (moderate to high digitized staining intensity values). High staining VEGF/FGF intensity was detected in 15/30 (50%), whereas the rest 15/30 (50%) demonstrated moderate expression. Among them, 13/15 cases co-overexpressed the markers. Overall VEGF/FGF expression was statistically significantly in pterygia compared to normal conjunctiva epithelia ($p = .0001$). Interestingly, recurrent lesions demonstrated the highest levels of VEGF/FGF co-expression. Additionally, the FGF levels were significantly related to the fleshy morphology of them ($p = 0.007$).

Conclusions: VEGF/FGF co-overexpression is frequently observed in pterygia playing a central molecular role in the progression of the lesion inducing also recurrent rates in sub-groups of patients. Cell spot array analysis -based on liquid cytology- seems to be an innovative, easy-to-use technique for analyzing digitized protein expression of multiple specimens on the same slide.



3rd Global Ophthalmology and Eye Diseases Summit

Biography

Stylianos Mastronikolis is a graduate from the University of Crete Medical School, Greece. Soon after my graduation I was enrolled as a PhD candidate of the University of Patras Medical School, Greece, and currently I hold a FY2 non-training post at the James Cook University Hospital, Middlesbrough, UK, seeking for an ophthalmology career at the NHS. I hope to deepen my knowledge in all aspects of this challenging specialty; however I would like to subspecialize in Oculoplastics and Orbital Surgery. I have also a particular interest for Oncology and this is demonstrated from my published work on Carcinogenesis and Tumor Markers. I have attended many courses, congresses, seminars, etc trying to continuously deepen my medical knowledge. Apart from my academic activity, I am practicing on martial arts, play guitar and bouzouki and I have an active volunteering role in various social events.



Allocation scheduling leads to optimum utilization of operation theater time

Meeta Tyagi¹, P.K. Tyagi², Sanjeet Singh³, Sidhartha Satpathy⁴, Sunil Kant⁵, Shakti Kumar Gupta⁶ and Rajvir Singh⁷

¹Ex. All India Institute of Medical Sciences, India

²Government Institute of Medical Sciences, India

³Indian Institute of Management, India

⁴All India Institute of Medical Sciences, India

⁵HQ Eastern Command, India

⁶Dr Rajendra Prasad Centre of Ophthalmic Sciences, AIIMS, India

⁷Venu Eye Institute & Research Centre, India

Background: Cancellation of surgeries is a regular phenomenon in any hospital. The reasons may vary from clinical to managerial ones.

Objective: To suggest scheduling to address the problem of time over run related cancellations.

Study design and sampling: Descriptive study conducted in a tertiary care ophthalmic hospital. The sample size is calculated with 95% confidence interval using Epi Info 6 and sample size arrived at n=380. Stratified random sampling technique was used.

TABLE 1: Idle Operation Theater Time Observed

Day	Unit	Type of OR	No. of ORs Available (a)	No of cases planned	Available OR Time (540Xa) (b)minutes	Total Makespan Time (C _{max}) (c)minutes	Available Idle OT Time (b-c) minutes
DAY 1	Unit A	GA	2	6	1080	412	668
		LA	4	44	2160	1684	476
		TOTAL	6	50	3240	2096	1144
	Unit B	GA	2	13	1080	1068	12
		LA	6	53	3240	3204	36
		TOTAL	8	66	4320	4272	48
TOTAL		14	116	7560	6368	1192	
DAY 2	Unit A	GA	2	13	1080	980	100
		LA	5	49	2700	2125	575
		TOTAL	7	62	3780	3105	675
	Unit B	GA	2	24	1080	1456	-376
		LA	5	21	2700	950	1750
		TOTAL	7	45	3780	2406	1374
TOTAL		14	107	7560	5511	2049	
DAY 3	Unit A	GA	1	10	540	929	-389
		LA	6	33	3240	3066	174
		TOTAL	7	43	3780	3995	-215
	Unit B	GA	3	23	1620	1080	540
		LA	4	39	2160	1408	752
		TOTAL	7	62	3780	2488	1292
TOTAL		14	105	7560	6483	1077	

3rd Global Ophthalmology and Eye Diseases Summit

Methods: Surgical time for all types of ophthalmic surgeries (n = 582) was observed. Allocation of listed cases to the available operating rooms (ORs) was carried out using the observed time using LEKIN software.

Results: The time over-run of 2 h and 6 h was noted for two units, whereas idle OR time was observed in other units. An average idle time of

19% was noted on each day. Table 1 shows the available idle time.

Conclusions: Planning of cases using procedure time and scheduling on a daily basis using allocation models with simple algorithms can provide optimal utilization of OTs and can address the time over-run and related cancellations.

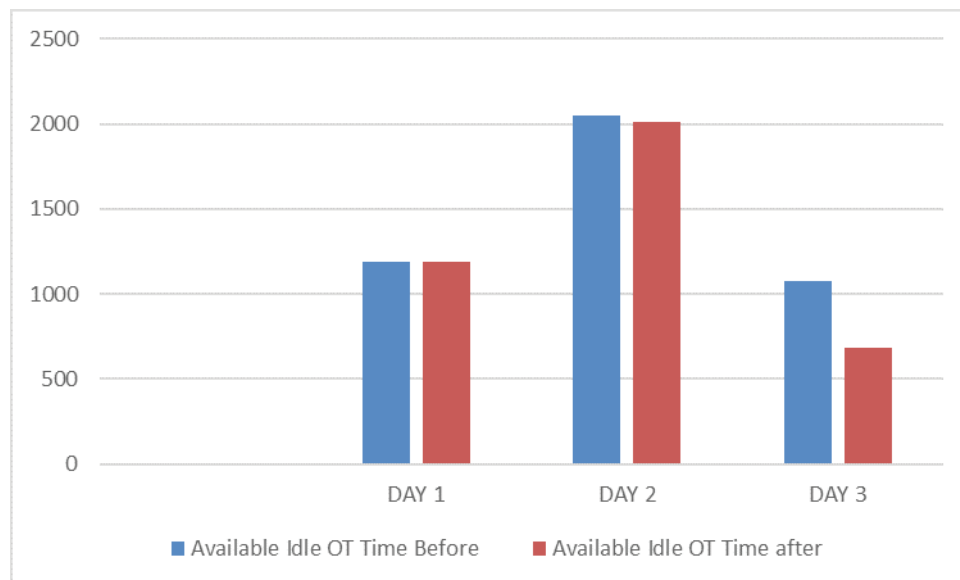


Figure 2: Comparison of Idle Operation Theater time before and after scheduling

Biography

Meeta Tyagi is working at All India Institute of Medical Sciences, India



Identifying diabetes from conjunctival images using a novel hierarchical multi-task network

Xinyue Li¹ and Hong Zhang²

¹Shanghai Children's Hospital, Shanghai Jiaotong University, China

²The First Affiliated Hospital of Harbin Medical University, China

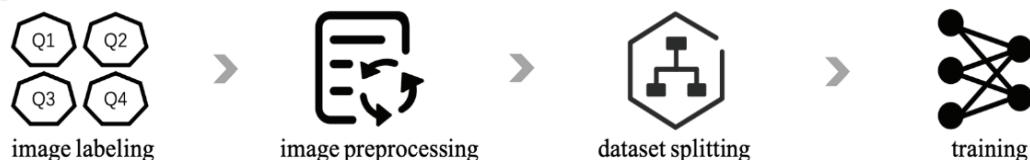Diabetes can cause microvessel impairment. However, these conjunctival pathological changes are not easily recognized, limiting their potential as independent diagnostic indicators. Therefore, we designed a deep learning model to explore the relationship between conjunctival features and diabetes, and to advance automated identification of diabetes through conjunctival images. Images were collected from patients with type 2 diabetes and healthy volunteers. A hierarchical multi-tasking network model (HMT-Net) was developed

using conjunctival images, and the model was systematically evaluated and compared with other algorithms (Figure). The sensitivity, specificity, and accuracy of the HMT-Net model to identify diabetes were 78.70%, 69.08%, and 75.15%, respectively. The performance of the HMT-Net model was significantly better than that of ophthalmologists (Table). The model allowed sensitive and rapid discrimination by assessment of conjunctival images and can be potentially useful for identifying diabetes.

A. Data collection



B. Model development



C. Evaluation



3rd Global Ophthalmology and Eye Diseases Summit

Table. Performance of artificial intelligence vs ophthalmologists in identifying diabetes based on conjunctival images

	SE (%)	SP (%)	ACC (%)	Speed (s/image)
HMT-Net	78.70	69.08	75.15	1.24
Human average	59.02	42.11	51.59	7.76
ophthalmologist 1	70.10	55.26	63.58	9.21
ophthalmologist 2	62.89	38.16	52.0	6.24
ophthalmologist 3	64.95	18.42	44.51	8.25
ophthalmologist 4	38.14	56.68	46.24	7.35

SE=Sensitivity, SP= Specificity, ACC= Accuracy.

Biography

Li Xinyue is a junior doctor in Shanghai Children's Hospital. The objectives of her research are (i) application of deep learning in ophthalmology and (ii) myopia in children. She has Phd degree from Harbin Medical University in ophthalmology. She speaks Chinese and English. If you are interested in her research topics, please feel free to contact her via email: lixinyuexinyue@foxmail.com.

Ophthalmology and Eye Diseases Summit



Cognitive AI for real time prognosis of multimodal genomic and ophthalmic impairments

Ajakwe Simeon Okechukwu¹, Ajakwe Ihunanya Udodiri², Dong-Seong Kim³ and Jae Min Lee⁴

^{1,3,4}Department of IT Convergence Engineering, Kumoh National Institute of Technology, South Korea

²Department of Biochemistry, Federal University of Technology, Nigeria

Real-time and early fundus screening and accurate detection of ophthalmic diseases are of huge economic value in ubiquitous smart-healthcare delivery with ophthalmology inclusive. With sporadic advancement in medical practice due to the emergence of disruptive technologies, it is believed that access to quality health services and eye-disease treatment through informed domain knowledge can be guaranteed. However, accessing reliable and viable clinical datasets for dependable complex diagnosis for preventive and curative purposes remains a daunting challenge. Curative innovation demands a sophisticated lightweight framework that relies on a smaller dataset for contrastive and dependable decisions. This work focuses on developing a self-supervised learning model that leverages multimodal embedded heterogeneous data fusion for intelligent,

contrastive, and proactive recognition and detection of ocular diseases. The dataset comprises 10,000 fundus samples of 8 disease categories such as Glaucoma, Maculopathy, Pathological Myopia, Retinitis Pigmentosa, etc., captured from about 5,000 patients. Model training and testing were carried out in a python environment and evaluated using defined performance metrics. The results reveal that with the application of a self-supervised learning model, ophthalmologists can leverage the possibilities of artificial intelligence for both prevention and curation of genomic-eye disease, especially for reinforced expert feedback through digital twin and the metaverse. Abstract should give clear indication of the objectives, scope, results, methods used, and conclusion of your work. One figure and one table can be included in your results and discussions.

Biography

Simeon Okechukwu Ajakwe works at Networked System Laboratory, IT Convergence Engineering Department in Kumoh National Institute of Technology, Gumi, South Korea. Simeon is a Chartered Information Technology Professional (Citp) with over 14 years of IT-related industrial and academic experience. He is a member of IEEE, Computer Professionals of Nigeria (CPN), and Nigeria Computer Society (NCS). Currently, he is the research and project leader of the Anti-drone Surveillance System as well as the Water Quality Monitoring System. His research domain cuts across Artificial Intelligence for real-time systems, Deep Learning and Computer vision, Software Engineering, Information Systems, and Security. He is a reviewer for different reputable peer-reviewed journals and has authored several publications in AI, software engineering, and information systems.

Efficacy of honey-based eye drop to relieve ocular signs and symptoms in dry eye: A systematic review

D. Permatasari and S. Widyawati

*Department of Ophthalmology, Cipto Mangunkusumo Hospital
Kirana, Indonesia*

Dry eye is among the most common ocular pathologies. It is associated with inflammation due to stressor, one of them is ocular flora imbalance. Treating the microbes using antibiotics poses resistance issue and alternative is needed. Honey has been well known for its antimicrobial and antiinflammatory traits and its role in wound healing. This review aims to review the efficacy of honey eye drop in relieving dry eye of any type.

Searching was done in three database: Pubmed, Cochrane, and Google Scholar. Clinical trials that fulfill eligibility criteria and clear measurements were included. Parameters to be reviewed were ocular symptoms, tear film instability, tear volume, tear composition, and ocular damage.

Three studies were included. All of them were

done in Australia to adult dry eye subjects and used Manuka honey eye drop. Control were artificial tears in all studies. Dry eye symptoms in honey group improved significantly compared to control group. However, improvement of dry eye signs in honey eye drop was not consistently significant compared to control group. Participant masking was an issue due to distinctive smell of honey eye drop. No serious adverse reaction was found.

Honey eye drop improved dry eye symptoms significantly better than artificial tears but not significantly improved dry eye signs compared to artificial tears. Participant masking should be considered to this finding. Further studies were required to confirm the role of honey in relieving dry eye.

Biography

Dr. Dita Permatasari graduated as a medical doctor from Faculty of Medicine, Universitas Indonesia in 2015 and worked in rural area of East Nusa Tenggara before entered medical residency at Department of Ophthalmology, Cipto Mangunkusumo Hospital Kirana, Faculty of Medicine Universitas Indonesia at 2019. Been working in a developing country, from rural area to the national referral centre, she realized the importance of therapies that are sustainable and could be abundantly available for all demographic classes.



Diabetes retinopathy detection using deep learning

Samira LAFRAXO

Department of Computer Science, Ibn Zohr University, Morocco

Diabetic retinopathy is the major cause of blindness in the world's population. It is predicted that approximately 93 million individuals would be affected. Diabetes is estimated to affect 29.1 million people in the United States by The US Center for Disease Control and Prevention, and 347 million people globally by the World Health Organization. Diabetic Retinopathy (DR) is an eye disease caused by long-term diabetes. Around 40% to 45% of diabetics in the United States are in some stage of the illness. Development to impaired vision can be delayed or avoided if DR is diagnosed early, but this can be challenging because the disorder frequently manifests few symptoms until it is too late for effective treatment. Detecting DR has become a time-consuming and laborious technique that necessitates a professional physician examining and evaluating digital color fundus images of the retina. When human readers write their evaluations, which is usually a day or two later,

the postponed findings result in missing follow-up, misunderstanding, and delayed diagnosis. Clinicians can recognize DR by the appearance of lesions related with the disease's vascular anomalies. While this strategy is effective, it has a significant resource need. The necessary skills and equipment are frequently insufficient in places where the prevalence of diabetes is considerable and DR recognition is most required. As the number of diabetics increases, the infrastructure required to prevent DR-related blindness will become increasingly more inadequate. The necessity for a thorough and automated approach of DR screening has long been noted, and prior attempts employing image classification, pattern recognition, and machine learning have made significant progress. The purpose of this study, using color fundus images as input, is to push an automated detection system to its limits, hopefully resulting in models with realistic clinical promise.

Biography

Samira Lafraxo received her Master degree in Distributed Systems from The University of Ibn Zohr, Agadir, Morocco in 2016. She is currently a Ph.D. candidate in the LabSIV laboratory, Ibn Zohr University. Her main research interests include image processing, computer vision, artificial intelligence and medical imaging.

3rd Global Ophthalmology and Eye Diseases Summit



Late presentation of a patient with a traumatic subconjunctival crystalline lens dislocation

Murat Okutucu

Department of Ophthalmology, Recep Tayyip Erdoğan University, Turkey

Objective: To report the clinical findings of a patient whose crystalline lens was dislocated into the subconjunctival area because of trauma.

Methods: An 83-year-old female patient presented with complaints of decreased vision due to trauma to the right eye and a mass in the superotemporal subconjunctival area, 2 months after the event. Anterior segment color imaging, B-scan ultrasonography (USG), surgical removal of the crystalline lens in the superotemporal subconjunctival region, and histopathological examination of the lens were performed.

Results: Her visual acuity was counting fingers at 1 meter and 3/10 for the right and left eye respectively. Biomicroscopic examination revealed a round, translucent mass of the dislocated lens in the superotemporal subconjunctival area of the right eye, multiple tears in the iris sphincter, corectopia of the pupil towards the closed scleral wound, vitreous strands in the pupillary area, and an aphakic eye (Fig 1A). B-scan USG showed that the integrity of the globe and retina was intact and there was no hemorrhage in the

vitreous (Fig 1B). A corticonuclear cataract was observed in the left eye. Intraocular pressure was 16/13 mmHg. The patient then underwent surgery. The conjunctiva was explored, and the capsule of the crystalline lens was found to be intact; however, the capsule was ruptured while removing the lens. Calcification was observed on the lens (Fig 1C). The superotemporal scleral rupture line, 1.5 mm from the limbus closed spontaneously. Histopathological examination of the lens revealed hyalinization and degeneration. The risks and complications were explained to the patient, and pupilloplasty and scleral fixation intraocular lens implantation were recommended; however, the patient refused.

Conclusion: This case report shows that, after dislocation of the crystalline lens to the subconjunctival area, the lens can remain with its capsule for a long time without resorption, and scleral rupture can close spontaneously without any permanent complications in the posterior segment. In addition, prolonged exposure of the lens to the subconjunctival area causes calcification, hyalinization, and lens degeneration.

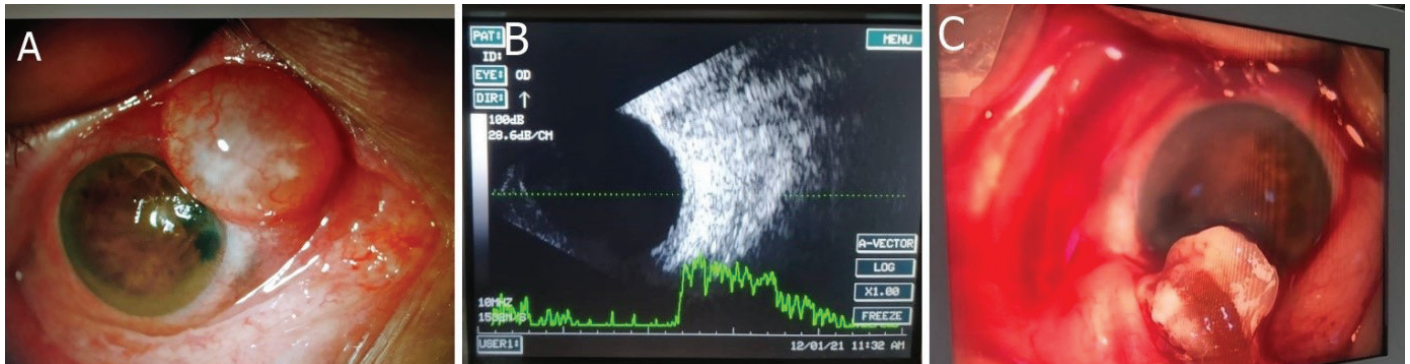

Figure 1. Biomicroscopic examination revealed subconjunctival dislocated lens, iris damage, corectopia, and aphakic eye (A). In B-scan USG, the globe, and retina were intact and there was no hemorrhage in the vitreous (B). An intraoperative image revealed a removed crystalline lens with calcification (C).

Biography

Murat Okutucu has been working as an assistant professor at Recep Tayyip Erdogan University in Turkey for the past 5 years and have 13 years of experience in the field of ophthalmology. My primary interests are retinal diseases and vitreoretinal surgery. I am a member of the Turkish Ophthalmology Association. I have over 20 articles and case reports published in national and international journals.



Impact of cisplatin administration on cerebellar cortical structure and locomotor activity of infantile and juvenile albino rats: The role of oxidative stress

Mohey A.E. Hulail, Hanan E.L. Mokhtar,
 Samar Mortada Mahmoud and Doaa Mohammed Yousef
Human Anatomy and Embryology, Zagazig University, Egypt

Objectives: To evaluate the effect of cisplatin on the postnatal development of cerebellum of albino rats.

Scope: Cisplatin is a platinum compound very effective as a cancer therapy. It is one of the most widely used chemotherapeutic agents. However, it is highly toxic and has dose-limiting side effects including hepatotoxicity, neurotoxicity, nephrotoxicity, and ototoxicity. The mechanism of CisPt-induced neurotoxicity is unclear. This study was designed to evaluate its effects on postnatal development of rat cerebellum.

Methods: Eighty infantile rat pups (10 days old age) were used in this study.

For evaluating the locomotor activity, 20 rats were divided into equal 2 groups; control group kept without any treatment and CisPt-treated group received (5 µg/g b.w.) by subcutaneous injection in their nape at PD10.

For histological study; 60 rats were divided into equal two groups; control group subdivided into equal three groups sacrificed at postnatal days 11, 17 and 30 respectively and Cisplatin treated group. Each rat received (5 µg/g b.w.) by subcutaneous injection in their nape at

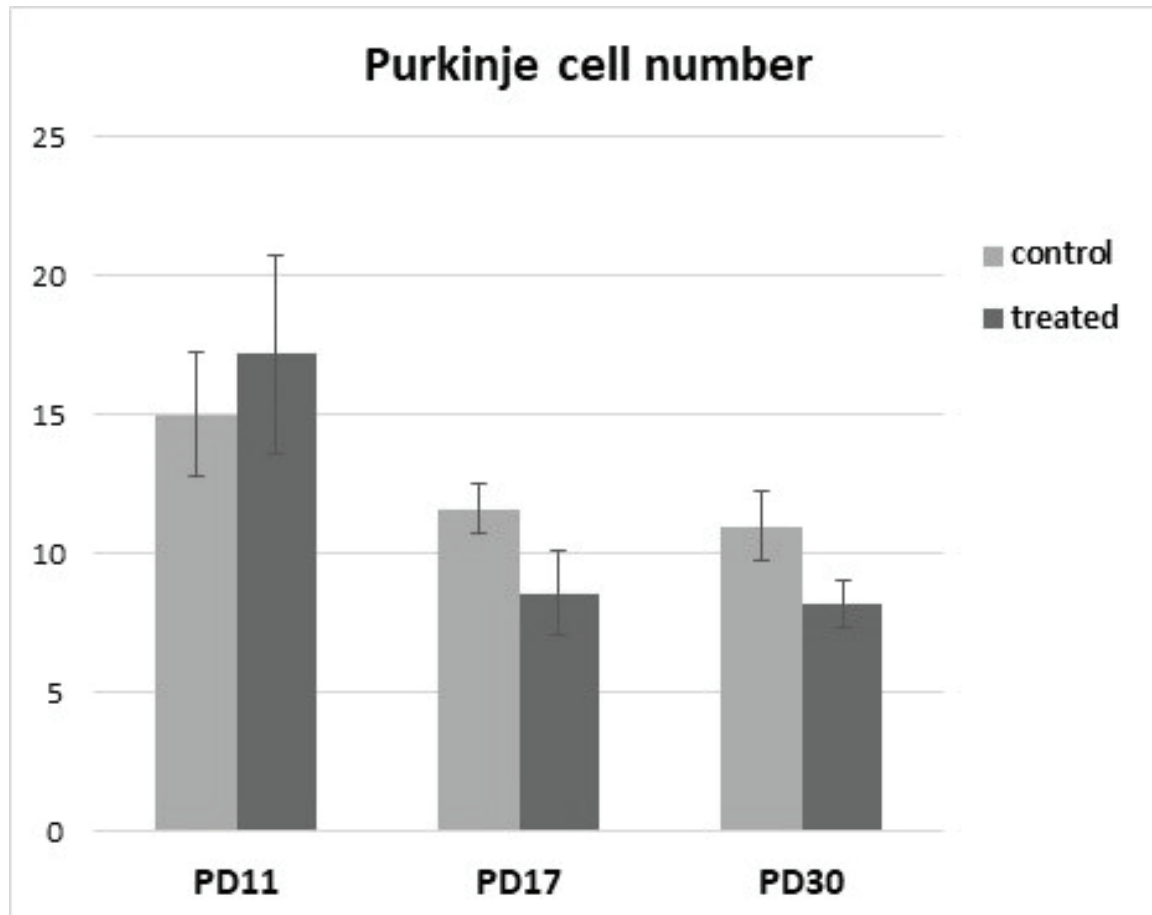
PD10 then divided into three groups sacrificed at postnatal days 11, 17 and 30 respectively

Results: Physiologically CisPt-treated rats had decreased body and cerebellar weights, and decreased motor activity

Histologically CisPt caused decreased thickness, vacuolations and hemorrhage within the cortical layers of the cerebellum. Purkinje cells showed profound degenerative effects in the form of swelling, distortion, nuclear shrinkage, and disrupted arrangement.

Histochemistry CisPt-treated rats, GFAP showed upregulated, hypertrophied, branched Bregman glial fibers and reactive astrogliosis. Immunolocalization of Ki-67 positive cells revealed oxidative stress and defective migration associated decreased proliferation in early ages in addition to glial proliferation in PD30.

Conclusion: CisPt causes toxic effects on the histological structure of the developing cerebellar cortex, decreased enzymatic antioxidants (SOD and CAT) and the non-enzymatic antioxidant defense (GSH) and increased lipid peroxidation marker (MDA). and affects locomotor activity.



Biography

Prof. Dr Mohey hulail a professor of anatomy and embryology, faculty of medicine zagazig university egypt. He is a Chaiman and head professor of the department.

I have recently many researches in medical education - Our researches deal with the possible protective effects of supposed materials either chemicals or nutritional to ameliorate the toxicity of drugs used in treatment of high risk diseases or on Preservatives, paints, anti-insects, mosquitoes, etc.

3rd Global Ophthalmology and Eye Diseases Summit

Single nucleotide polymorphism of receptor for advanced glycation end- products [rage] gene: Is it a new opening in the risk assessment of diabetic retinopathy?

Pragya Ahuja

Jawaharlal Nehru Medical College, Aligarh Muslim University, India

Diabetic Retinopathy (DR) is a common microvascular complication of diabetes. There is strong evidence suggesting that DR has an inheritable component. The Receptor for Advanced Glycation End Product (RAGE) gene is one of the crucial genes involved in the pathogenesis of various complications of diabetes mellitus, retinopathy being one of them. This review discusses the existing literature on the association between single nucleotide polymorphism (SNP) of RAGE gene and the risk of DR. It also discusses the current understanding of the AGE-RAGE pathway in diabetic retinopathy. A literature

review was performed on PubMed, Cochrane Library and Google Scholar for studies to find existing literature on the association between RAGE gene SNPs and the risk, progression and severity of developing DR. It has been observed that gene polymorphism is highly variable when ethnicity and demography is concerned. Further studies involving large multicentric genome-wide assays encompassing diverse phenotypic and ethnic groups could be beneficial in establishing it as a genetic marker for the management of DR in the coming future.

Biography

Dr Pragya Ahuja is currently a second year junior resident doing her masters in surgery course in Ophthalmology from Institute of Ophthalmology, Jawahar Lal Nehru Medical College, Aligarh Muslim University, Aligarh. She has completed her MBBS from Lady Hardinge Medical College, Delhi University. She is currently pursuing her thesis on Diabetic Retinopathy under the mentorship of Dr Abdul Waris. An avid learner she has a keen interest in vitreoretinal diseases and aspires to become a vitreoretinal specialist in the future.



Acute angle-closure glaucoma after total knee replacement surgery: A Case report

O. Terkaouchi and S. Ketata

*Department of Anesthesiology and Critical care,
 Habib Bourguiba Hospital, Tunisia*

Introduction: Acute angle closure glaucoma (AACG) after non-ocular surgery is a rare complication of general anesthesia. However, in case of delayed diagnosis, it may lead to blindness. An immediate diagnosis and an appropriate treatment should be done to prevent visual loss.

The case report: We present a case of a 65 years-old monophthalmus man who was operated for a total knee replacement surgery, under general anesthesia without any adverse events. The day after, the patient described recurrent periorbital pain in his eye, with ocular hyperemia, and reduced visual acuity. A diagnosis of AACG was made and conservative treatment was started to reduce the intraocular pressure. The next day,

the intraocular pressure was normalized, and visual acuity was completely recovered. In the present case, 3 possible triggering factors could be incriminated: stress, the use of atropine for decurarization, and nefopam for postoperative analgesia.

Discussion: In the post operative AACG, several predisposing local factors including genetic predisposition, female gender, hypermetropia, increased lens thickness and small corneal diameter, can be added to a pupillary block induced by adrenergic and anticholinergic drugs used in anesthetic procedures as risk factors.

Conclusion: An acute and intensive periorbital or ocular pain, with or without visual disturbance, must aware the physician.

Biography

Omar tarkaouchi is working in the Department of anesthesiology and intensive care at Habib Bourguiba hospital, Tunisia



Coexistence of posterior polar annular and hemispheric choroidal dystrophy: A case report

Murat Okutucu¹ and Şenol Çitli²

¹Department of Ophthalmology, Recep Tayyip Erdoğan University, Turkey

²Department of Medical Genetics, Recep Tayyip Erdoğan University, Turkey

Objective: To report the clinical findings of a patient with posterior polar hemispheric choroidal dystrophy of the right eye and posterior polar annular choroidal dystrophy of the left eye.

Methods: A 42-year-old female patient stated that she was diagnosed with retinitis pigmentosa approximately 10 years ago and presented to the eye clinic for routine control every 2–3 years. A detailed ophthalmological examination, color fundus photography, fundus fluorescein angiography (FFA), optical coherence tomography (OCT), and genetic mutation analysis were performed.

Results: The best-corrected visual acuity was 6.25 (-3.00□15) to 0.5 and 5.25 (-2.25□180) to 0.2 on the right and left eyes, respectively. Biomicroscopic examination was unremarkable. She had been diagnosed with amblyopia in childhood due to strabismus and high refractive error. Intraocular pressure was 16/14 mmHg. Dilated fundus examination revealed hemispheric retinal and choroidal atrophy around the superior arcade of the right eye and hyperpigmentation of the retina (Fig 1A). Similar changes were observed as annular in the posterior pole of the left eye (Fig 1B). Both eyes exhibited retinal pigment epithelial (RPE) atrophy in the temporal retina.

In FFA, hypofluorescence due to blockage caused by hyperpigmentation in the area corresponded with a lesion of the right eye, and hyperfluorescence due to RPE atrophy in the temporal retina was observed (Fig 1C). In the left eye, hypofluorescence caused by hyperpigmentation in the area corresponding to the annular lesion and hyperfluorescence due to RPE atrophy in the temporal retina were observed (Fig 1D). OCT macula was unremarkable. Genetic mutation analysis was performed by the Medical Genetics Department. The patient was determined to be carrying the PRPH2 (RDS/peripherin) gene with p.Asn295Lys (c.885C>A) heterozygous variation. Genetic mutation analysis of the 21-year-old daughter of the patient revealed that she carried the same genetic mutation as her mother. All ophthalmological examination findings of the daughter were normal.

Conclusion: Although posterior polar hemispheric choroidal dystrophy and posterior polar annular choroidal dystrophy have been defined as different diseases, this case report shows that posterior polar hemispheric choroidal dystrophy may represent an early stage of posterior polar annular choroidal dystrophy. The RDS/peripherin gene mutation observed in many central retinal dystrophies may be a causative factor in this disease.

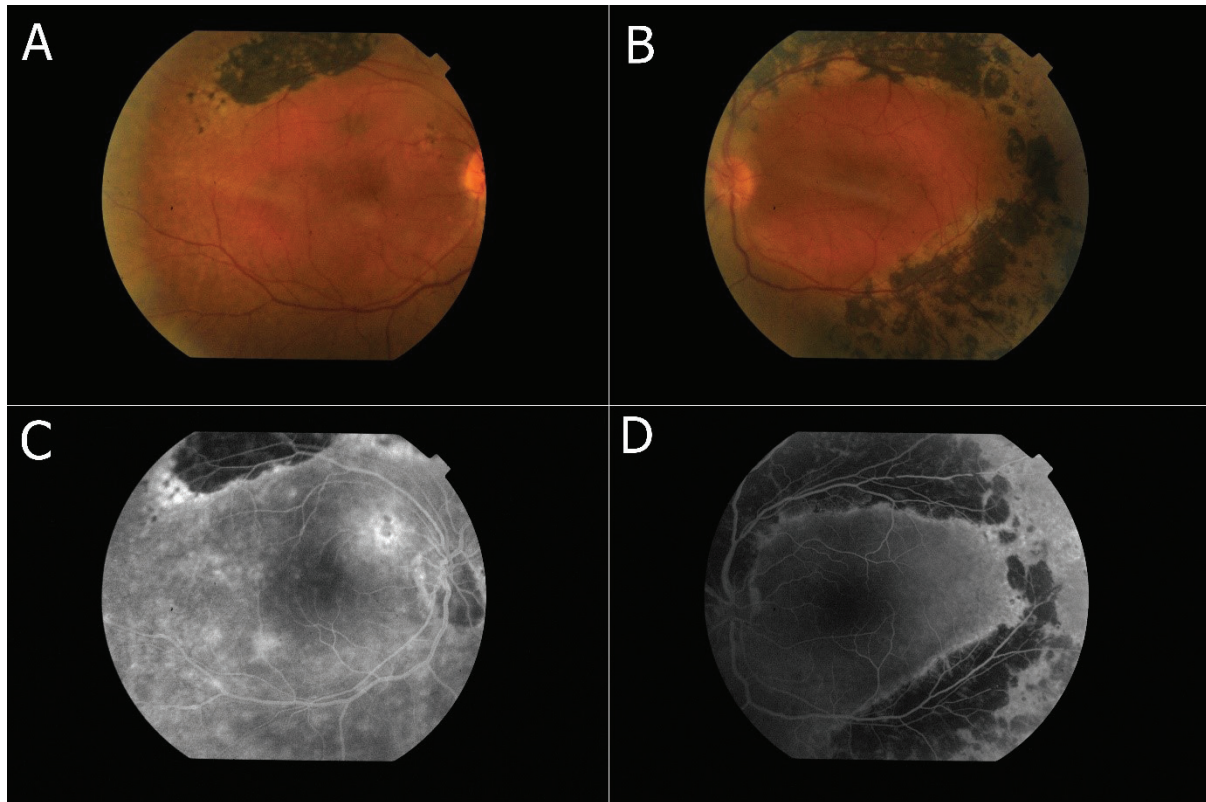


Figure 1. Color fundus photograph revealed hemispheric retinal and choroidal atrophy around the superior arcade of the right eye and hyperpigmentation of the retina. The lesion is annular in the left eye (A, B). FFA revealed hypofluorescence due to blockage caused by hyperpigmentation in the area corresponded with a lesion and hyperfluorescence due to RPE atrophy of the right and left eye respectively. (C, D).

Biography

Murat Okutucu has been working as an assistant professor at Recep Tayyip Erdogan University in Turkey for the past 5 years and have 13 years of experience in the field of ophthalmology. My primary interests are retinal diseases and vitreoretinal surgery. I am a member of the Turkish Ophthalmology Association. I have over 20 articles and case reports published in national and international journals.



Awareness and attitudes of art students and lecturers on health hazards associated with fine and applied arts making in Nigeria

Christopher Ifeanyi Ibenegbu¹, RitaDoris Ubah²
and Queendaline Obiajulu Ibenegbu³

¹Department of Arts Education, University of Nigeria, Nigeria

²Department of Fine and Applied Arts, University of Nigeria, Nigeria

³Department of Science Education, University of Nigeria, Nigeria

Background: Art-making can pose significant risks to the health and safety of artists. Some art materials and equipment are hazardous.

Objective: This article highlights the various hazards caused by the use of these materials in art-making and actions that could be taken to prevent it.

Methods: We used documentary research approaches to find out and study the relevant literature sources and to analyze and synthesize the information got.

Result: The results showed that art students

and lecturers are not aware of the health hazards of art materials they use in their art practice, and they have a nonchalant attitude towards taking appropriate health precautions in the use of these art materials. We also observed that changing the attitudes of university art students, and lecturers on the health hazards involved in art-making would require several actions.

Conclusion: The awareness of health hazards associated with art-making/studio practice is useful to help art students and lecturers to increase their health precautions in using art materials.

Biography

Christopher Ifeanyi Ibenegbu is in the Department of Arts Education, Faculty of Education, University of Nigeria, Nsukka. His research interests include the integration of ICT in teaching and learning of Fine and Applied Arts, Illustration of children's books, designing and production of instructional materials for effective and efficient teaching and learning, web designing, e-learning activities, very proficient in general computer applications, high skill in research and computer analysis. He is one of the active Nigerian uli artists. He is one of the resource persons at Asele Institute, Nimo. This is an Art institute founded by Professor Uche Okeke. He is currently a Senior Lecturer in the Department of Arts Education and has supervised BA (Ed) Undergraduate and Postgraduate projects. He has participated in solo and many group art exhibitions. He has published many papers in some local and international journals.



Covid-19 pandemic and risk of myopia

Rozhan Khezri¹, Fatemeh Rezaei² and Fateme Darvish Motevalli³

¹Department of Epidemiology, Iran University of Medical Sciences, Iran

²Department of Social Medicine, Jahrom University of Medical Sciences, Iran

³Department of Medical Laboratory Sciences, Iran University of Medical Sciences, Iran

COVID-19 is the first infectious disease pandemic in the 21st century. To fight it, lockdown, social distancing, and staying at home strategies were implemented. The COVID-19 pandemic has also affected educational systems around the world so that many students had to attend online classes. Online classes were one of the solutions to decrease the risk of infection. Through this, learners and instructors used online platforms and screens for long hours to attend their classes. There were also lifestyle changes. To prevent COVID-19 infection, people had to stay at home and limit their social interactions to online platforms and social media. Long hours of using displays increase the risk of sight disorders and refractive errors. Myopia is a common refractive error in many countries. Refractive errors represent about one-half of visual impairments and the second cause of functional blindness. Watching TV, computer games, using laptops, and the like

increase the risk of Myopia. There is a negative relationship between Myopia and the time spent outside the home. The risk of developing Myopia is higher during the COVID-19 pandemic as many students, university students, teachers, professionals, and many others must use online platforms to work. In addition, lockdown and spending long hours at home increase the time spent with mobile phones, laptops, and so on. Therefore, Myopia is one of the challenges that might appear in human societies following the pandemic. Given the importance of the disorder and its effect on the quality of life, there is a need for timely intervention and educational plans to inform the public. Along with public vaccination and booster injections, the ground for the presence of people in social and educational fields should be provided to promote social interactions in society. Parents are also recommended to spend a few hours every day outside with their children.

3rd Global Ophthalmology and Eye Diseases Summit

Biography

My name is Rozhan Khezri. I live in Iran. I'm in my mid-thirties. I am a PhD student in epidemiology at the Iran University of Medical Sciences.

I am recently researching secondary studies. I have also acceptance for Several meta- analysis Commentary and original research entitled:

- Prevalence of Syphilis Infections among the Iranian Population: A Systematic Review and Meta-analysis
- Survival Rate of Liver Transplantation in Asia A Systematic Review and Meta-Analysis
- covid19 vaccine and the necessity to identify its side effects
- Electronic-Cigarette (Vapors) Smoking and the Risk of COVID-19
- Similarities between COVID-19 and Leptospirosis Signs and Symptoms may lead to Delay in Diagnosis and a Misleading increase in reported cases of COVID-19
- CoronaVirus Anxiety and Resilience: comparisons in medical staff and non-medical staff in Iran
- Prevalence and pattern of antibiotic resistance of microbial agents in preterm neonatal sepsis
- The Knowledge and Attitude of the Parents of Children with ADHD toward Methylphenidate (Ritalin)



Investigating the mechanisms behind the development of acquired resistance to Anti-VEGF therapy in neovascular diabetic eye disease

Dhyana Sharma¹, Ian Zachary² and Haiyan Jia¹

¹Biotherapeutics Group, Research & Development, Medicines and Healthcare products Regulatory Agency (MHRA), UK

²Department of Medicine, University College London (UCL), UK

Diabetes can cause vision loss through severe retinal microvascular complications, leading to the development of proliferative diabetic retinopathy (PDR) and diabetic macular edema (DME). Abnormal angiogenesis and increased vascular permeability are the major pathophysiological features of both diseases and are exacerbated by the over-expression of vascular endothelial growth factor (VEGF). Anti-VEGF biologic drugs bind VEGF to perturbate pathological angiogenesis. Clinical findings present a decrease in efficacy in some patients after treatment, suggesting the development of acquired resistance. The present study examines the mechanisms behind this in vitro, focusing on neuropilin-1 (NRP-1) and its ligands, which have been associated with pathophysiological features of PDR and DME independently to VEGF.

Human retinal microvascular endothelial cells (HRMECs) have been characterized as a cellular model for this project. The effects of anti-VEGF treatment on NRP-1 and NRP-1 ligands were measured by treating HRMECs with

repeated bevacizumab over 10 days. Samples were collected over the treatment period for examination of changes in cell surface expression of NRP-1 and secretion of NRP-1 ligands. NRP-1 blocking antibody was applied to co-cultures of endothelial cells and fibroblasts, an in vitro model of angiogenesis, and HRMEC-seeded transwell inserts, an in vitro model of the blood-retinal barrier, to assess microtubule formation and cellular permeability respectively.

HRMEC surface expression of NRP-1 increases after repeated treatment of bevacizumab, with downregulated secretion of its ligand, placental growth factor. Further studies suggest the latter may be an indirect effect of VEGF blockade. NRP-1 inhibition elicits an angiostatic effect on endothelial cells, independently to bevacizumab. These findings suggest a role of NRP-1 and NRP-1 ligands in retinal endothelial growth and differentiation independently to VEGF, potentially uncovering a mechanism for the development of acquired resistance to anti-VEGF therapy in the retinal microvasculature.



3rd Global Ophthalmology and Eye Diseases Summit

Biography

Dhyana Sharma is a 3rd year PhD candidate at the National Institute for Biological Standards and Control (NIBSC, a branch of the Medicines and Healthcare products Regulatory Agency, MHRA) and University College London (UCL). Studying under Dr Haiyan Jia (NIBSC) and Professor Ian Zachary (UCL), her project investigates the mechanisms behind the development of acquired resistance to anti-VEGF therapy in neovascular diabetic eye disease, with particular focus on neuropilin-1 and its ligands. With her prior research encompassing elements of study into chemotherapy, chronic pain, childhood cancer, angiogenesis and neovascular eye diseases, Dhyana's background knowledge is broad. Her aim for the remainder of her study is to narrow down this broad knowledge and learn the intricacies of the many pathways researched within her PhD project.



Epigenetic changes in the promoter of the fragile histidine triad (FHIT) gene in human sebocytes under the influence of in vitro culture

Magdalena Jotzo

*Institute of Molecular Medicine, Martin-Luther-University
 Halle-Wittenberg, Germany*

Background: Due to the lack of tumor suppressor function of the fragile histidine triad (FHIT) gene product, sebaceous gland carcinomas can develop.

Objective: SZ95 sebocyte cells of increasing passages were analyzed for methylated CpG islands at the 5' -end of the FHIT gene and the decrease of gene expression as well as the increase of double-stranded (ds) DNA breaks.

Material and methods: Methylation, immunofluorescence analysis, promotor sequencing and treatment of SZ95 cells with 5-azacytidine/trichostatin A (TSA).

Results: The cultivation was accompanied by an increasing methylation of the CpG islands, a decrease of the FHIT gene expression and an accumulation of ds-DNA breaks. Treatment with 5-azacytidine/TSA showed a decrease in DNA methylation and a re-expression of FHIT transcripts.

Discussion: Epigenetic changes in the cellular genome are caused by in vitro cell culture. Consequently, a positive selection of sebocytes with an epigenetically inactivated FHIT locus occurs.

Biography

Magdalena Jotzo is working at the Institute of Molecular Medicine of Martin-Luther-University Halle-Wittenberg, Germany



Myasthenia gravis in patients treated with immune checkpoint inhibitors

Y. Shames

Memorial Sloan Kettering Cancer Center, USA

The use of Immune Checkpoint Inhibitors (ICI) over the past decade has transformed the landscape of cancer care by offering significant improvement in overall and progression free survival. Cytotoxic T-lymphocyte-associated protein 4 (CTLA-4) and program cell death protein 1 (PD-1) play a significant role in creating immune homeostasis and inducing a cancer-tolerant microenvironment. Contrastingly, monoclonal antibodies against CTLA-4 and PD-1 proteins block receptor-ligand interaction and facilitate an autoimmune response against the tumor antigen by inducing the demise of T-regulatory cells and upregulating the production of T-effector cells (Ramos-Casals et al., 2020).

The concept of immune-mediated adverse events (irAEs) has emerged in the use of monoclonal antibodies such as Ipilimumab (Yervoy), Nivolumab (Optivo), Pembrolizumab (Keytruda) and some others in treatment of several types of cancers. Common irAEs affecting gastrointestinal, respiratory, endocrine, cutaneous, and musculoskeletal systems are well described in the literature (Suzuki et al., 2017). Among others, rare but

serious neurologic adverse events including myasthenia gravis (MG) come into a view. Although the etiology of immune-mediated MG is not clearly understood, ICI thought to produce an exacerbated autoimmune response directed at acetylcholine receptors and receptor-associated proteins and stimulate production of antibodies to acetylcholine and muscle-specific kinase receptors.

The distinctive features of MG include fluctuating weakness in ocular, bulbar, facial, neck, limb, and respiratory muscles. Ocular MG was observed in approximately 50% of all patients in whom generalized symptoms developed within two years of the initial diagnosis (Pelak & Quan, 2021). All cases of immune-mediated MG were associated with high mortality and morbidity and required prolonged hospitalization. Medical management was targeted at respiratory support and symptom reduction with immunosuppressive therapies. Prompt consultation with a neurologist and use of a multidisciplinary approach was essential for establishing accurate diagnosis and effective treatment plan.



3rd Global Ophthalmology and Eye Diseases Summit

Biography

The presenter is a Board-Certified Acute Care Nurse Practitioner and a Certified Neuroscience Registered Nurse with twenty years of Advance Practice experience in general neurology, neuro-oncology, and clinical research including metastatic malignant melanoma and cellular therapeutics. In addition to the publications listed above, the presenter co-authored several abstracts accepted by ASCO, CITC, ONS, and AANN, and conducted podium presentations on relevant topics including an overview of neuro anatomy and physiology, management of neurological emergencies and altered mental status, treatment and management of patients with central nervous system metastasis, and management of immune-mediated adverse effects. In her current role, the presenter is involved in clinical research assessing efficacy and toxicity of immunomodulating therapies.



Electrophysiological analysis of traumatic optic neuropathy and traumatic brain injury among active military

Brandon Lucke-Wold

Department of Neurosurgery, University of Florida, USA

A prospective cohort study using electrophysiological Visual Evoked Potential (VEP) testing for traumatic optic neuropathy (TON) in context of known traumatic brain injury (TBI) has been performed to review and revise management protocol for active military personnel who have sustained concussions or sub-concussive injury. This new VEP protocol was incorporated with kinetic and static visual field testing to uncover occult cases of traumatic optic neuropathy as well as

aid in evaluation of patients with concussive or sub-concussive cases that do not meet current protocol for the diagnosis of moderate or severe TBI in the field. Furthermore, we have confirmed that military parachute jumpers (paratroopers) represent a high-risk group for undiagnosed TBI and traumatic optic neuropathy. We have urged that collaboration and development of safer helmet design would help reduce and prevent TBI and traumatic optic neuropathy for military personnel.

Biography

Brandon Lucke-Wold was born and raised in Colorado Springs, CO. He graduated magna cum laude with a BS in Neuroscience and distinction in honors from Baylor University. He completed his MD/PhD, Master's in Clinical and Translational Research, and the Global Health Track at West Virginia University School of Medicine. His research focus was on traumatic brain injury, neurosurgical simulation, and stroke. At West Virginia University, he also served as a health coach for the Diabetes Prevention and Management program in Morgantown and Charleston, WV, which significantly improved health outcomes for participants. In addition to his research and public health projects, he is a co-founder of the biotechnology company Wright-Wold Scientific, the pharmaceutical company CTE cure, and was a science advocate on Capitol Hill through the Washington Fellow's program.

He has also served as president of the WVU chapters for the American Association of Pharmaceutical Scientists, Neurosurgery Interest group, and Erlenmeyer Initiative Entrepreneur group. In addition, he has served as vice president for the graduate student neuroscience interest group, Nu Rho Psi Honor Society, and medical students for global health. He was an active member of the Gold Humanism Honor Society and Alpha Omega Alpha Honor Society. He is currently a member of the UF House Staff Council and Positive Culture Committee. He is married to Noelle Lucke-Wold and has two children. As a family, they enjoy running with their dogs, rock climbing, and traveling. In his spare time, Brandon frequently runs half marathons and 10ks together with his wife. Brandon also enjoys reading and discussing philosophy and playing chess. He is currently a Pgy4 neurosurgery resident at University of Florida with R25 funding and plans to pursue endovascular training.



Predominantly practiced leadership styles of chief nursing officers in healthcare organizations

Haroon Malak¹, William Lorman², Al Rundio³,
Denise Simion⁴ and Marian G. Simion⁵

¹Drexel University, USA

²Department of Health Science, Drexel University, USA

³Department of Nursing & Health Science, Drexel University, USA

⁴School of Business, Fitchburg State University, USA

⁵Department of Business & Technology, Fitchburg State University, USA

Objective: The objective of this research was twofold. 1) To identify which leadership style is predominant in magnet and non-magnet hospitals and 2) To determine if the servant leadership style was more suitable in the healthcare environments than transformational leadership style?

Participant: There were ten (n = 10) voluntary participants recruited from various acute care hospitals in the Tri-state area (New York, New Jersey, and Pennsylvania). In some instances, these participants were interprofessional who managed multiple key units of the organization i.e., nursing and operations. Forty percent (n = 4) participants worked in a magnet setting; whereas, sixty percent (n = 6) participants worked in a non-magnet facility.

Method: A qualitative study design was utilized for this research. A leadership research tool was developed for this study. The data collection consisted of pre-interview questionnaires as well as a 60 min interview with each participant.

Result: Fifty percent (n = 5) participants believed that they practiced servant leadership style and the remaining fifty percent (n = 5) believed that they practiced transformational leadership style; however, post-interview, it was determined that forty percent (n = 4) practiced transformational, while thirty percent (n = 3) practiced servant leadership, twenty percent (n = 2) practiced situational leadership, and ten percent (n = 1) practiced visionary leadership style. Thirty percent (n = 3) participants believed that the servant; whereas, seventy percent (n = 7) believed that the transformational leadership style was most beneficial for magnet hospitals.

Conclusion: This research finding demonstrated that transformational, servant, and situational leadership styles were predominantly being practiced among the participants. In summary, participants believed that transformational for magnet and servant for non-magnet hospitals were the best-suited leadership styles.



3rd Global Ophthalmology and Eye Diseases Summit

Biography

Dr Haroon Malak is a Business Administrator, Scientist, and Leader with an extensive research and development, formulation, crystallography, processing, and analytics experience. He has held various leadership positions in multiple companies. These included Sr. Global Manager in Research & Development, Sr. Business Analytics Manager, Sr. Imaging Scientist in Global Science & Technology, Sr. Scientist in Science & Discovery, Color Scientist in Analytical Science, Marketing Manager in a Marketing Research Firm, and Director of Human Resources at Health Insurance company. Dr. Malak has a Doctor of Health Science (DHSc.), Masters of Business Administration (MBA), and Masters of Science in Chemistry (MSc). Dr. Malak aims to prepare himself for additional leadership opportunities where he can integrate his scholarship knowledge of health and science into practice in the future.



Experiencing a Genetic Disease: Receiving and Transmitting

Catarina Seidi¹, Marta Patrão², Sara Guerra³,
Carla Roma Oliveira⁴, Álvaro Mendes⁵ and Liliana Sousa⁶

¹Departamento de Educação e Psicologia, Universidade de Aveiro, Portugal

²Departamento de Ciências Sociais, Universidade de Aveiro, Portugal

³Instituto Superior de Serviço Social do Porto, Universidade de Aveiro, Portugal

^{4,5}UnIGENE and CGPP – Centre for Predictive and Preventive Genetics, IBMC – Institute for Molecular and Cell Biology, i3S – Instituto de Investigação e Inovação em Saúde, Universidade do Porto, Portugal

^{4,6}Departamento de Educação e Psicologia, Universidade de Aveiro, Portugal

Transthyretin-related familial amyloid polyneuropathy (TTR-FAP) is an autosomal dominant and highly penetrant late onset neurological disease. Symptoms are clinically heterogeneous, progressive and very incapacitating, leading to severe motor impairment, dependency and premature death. There is no cure, but some therapeutic measures may slow down disease progression. Hereditary diseases may be considered as family legacies both in biological and psychosocial terms. This exploratory qualitative study adopted the Portuguese version of the Self-Confrontation Method to explore the affective meanings that TTR-FAP gene-positive carriers attach to this biological/genetic legacy. We focus their valuations on inheriting the disease-gene and (potentially) transmitting it to their descendants. Four participants (aged \geq 45; 3 men; all symptomatic and with children), recruited by the TTR-FAP patients' association, took part in the study. Participants' valuations were analysed thematically and PNOS indexes were calculated to characterize affective

patterns. The valuations mostly showed negative affective patterns in both positions (receiver and transmitter). The position of "receiver" comprised both negative (aggression and rage; impotence and isolation) and positive (mainly autonomy and success) affective patterns, while the position of "transmitter" was predominantly attached to negative affective patterns (impotence and isolation). When formulated in the position of "receiver", the focus was mainly self-centred, while when in the position of "transmitter" the focus was mainly towards the other (children and grandchildren). Furthermore, the content analysis of the valuations generated three themes: awareness, diagnosis, and treatment and adaptation. It highlights key moments in the process of adaptation to TTR-FAP. These results contribute to a better understanding on the affective and relational processes associated with the legacy of a genetic disease. It is also relevant to inform genetic counselling services and professionals about the feelings and concerns that accompany these patients.

Biography

Nádia Catarina Pereira Seidi, Born in Funchal, Portugal in 1997. Masters in health psychology and Neuropsychology from the University of Aveiro and doctorate student from the same academy, is doing research in the topic of inherited diseases while practicing psychology in healthcare.

SCIENTIFIC ABSTRACTS

DAY 2



Virtual Event

3RD GLOBAL

Ophthalmology and Eye Diseases Summit

September 12-13, 2022

NOVEL OPHTHALMOLOGY 2022



Ocular Syphilis

Zaira Fernanda Martinho Nicolau and Nilva Simeren Bueno de Moraes

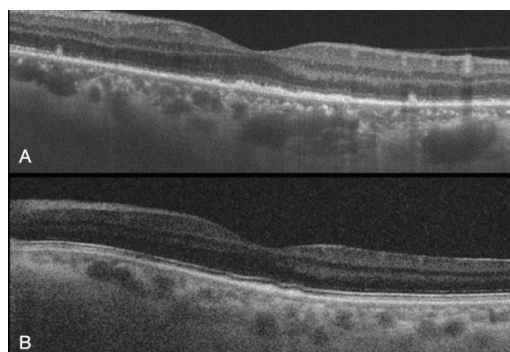
Department of Ophthalmology, Federal University of São Paulo, Brazil

Introduction: Ocular manifestations can occur at any stage of syphilis and it has various clinical presentations. If untreated, it may lead to long term complications and blindness.

Case report: A 51-year-old, Caucasian, male patient, complained of progressive central scotoma in left eye (OS) for 15 days. He had no significant past medical history. His best-corrected visual acuity (BCVA) was 20/20 (1.0) in the right eye (OD) and 20/80 (0.25) in OS. He had normal anterior segment, no relative afferent pupillary defect and intraocular pressure of 12 mmHg in both eyes. Fundus exam revealed a subretinal elevation in the left papillomacular bundle. Optical coherence tomography (OCT) depicts disruption of the photoreceptor inner/outer segment junction (IS/OS), multinodular hyperreflectivity of the RPE, and pachy vessels in OS. Fluorescein angiography revealed delay

in venous filling time, window defects, and optic disc leakage in OS. OD was unremarkable. Venereal Disease Research Laboratory (VDRL) was 1:128 and reactive treponemal test result. He was treated with ceftriaxone 2g intravenously daily for 14 days, with adequate serologic response. On the 3-month follow up, the patient had BCVA of 20/25 (0.8) in OS and improvement of OCT findings.

Conclusion: Syphilis can cause eye involvement in 0.6–2.7% of the cases, and this can be the only sign of this disease. It can be difficult to diagnose due to variable clinical presentations. So, it should be included as differential diagnosis in cases of uveitis, chorioretinitis, vasculitis, papillitis, among others. This knowledge is important for proper diagnosis, management, and favorable final visual outcome.



Left OCT at baseline (A) and 3-month follow-up (B).

Biography

Zaira Nicolau has MD degree from Federal University of São Paulo (UNIFESP) - Escola Paulista de Medicina. She completed her ophthalmology residency in Federal University of São Paulo. Currently she is a fellow of the Ophthalmology Department of Federal University of São Paulo, at the Retina division.

The effect of corneal epithelial redistribution difference on axial length elongation in myopic children with overnight orthokeratology

Yan Hua Wang, Yan Ming Kang, Jie Cheng
 and XinXiu Ren

Shanxi Aier Eye Hospital, Aier Eye Hospital Group, PR China

Objective: The myopia control effect of orthokeratology (OK) varies among individuals. This study evaluated the average height difference between flattening central cornea and relatively steepening mid-peripheral cornea (AHDCAP), axial length (AL), spherical equivalent, and assessed the effect of AHDCAP on AL elongation in myopic children treated with OK lenses.

Methods: Data from 178 myopic children treated with OK lenses (age range, 8 to 16 years) was assessed in the retrospective study. Corneal topography and AL were measured at baseline and 1, 6, and 12 months after OK lens wear. The AHDCAP was measured from the elevation subtractive map in corneal topography. The effect of the AHDCAP achieved at the 1 month post-OK. On the 12 months AL elongation was examined using correlation analysis.

Result: Baseline age of the study participants was 11.40 ± 2.34 years and their mean spherical equivalent was -3.50 ± 1.61 D. AHDCAP was negatively correlated with the AL elongation. The smaller AHDCAP was, the faster the AL growth ($P=0.001$, $r=-0.316$). There was a positive correlation between spherical equivalent and AHDCAP. The higher the myopia degree was, the higher the AHDCAP was ($P=0.000$, $r=0.469$). AHDCAP of low myopia group was less than that of moderate myopia group ($P<0.001$), and the AL growth in low myopia group was faster than that in moderate myopia group ($P<0.001$).

Conclusions: The difference of corneal epithelial redistribution is an important factor of axial length elongation in myopic children treated with overnight orthokeratology.

Biography

Yanhua Wang is a post-doctor, Chief physician at Shanxi Aier Eye Hospital, Aier Eye Hospital Group, China.

3rd Global Ophthalmology and Eye Diseases Summit



Subconjunctival foreign body with suspected scleral penetration

Suwarna Suman¹, Arushi Kumar² and
Hemant U. Rathod¹

¹Department of Ophthalmology, All India Institute of Medical Sciences Jodhpur, India

²Department of Transfusion Medicine, Postgraduate Institute of Medical Education and Research, India

Ocular foreign bodies may be a threat to vision loss. Superficial foreign bodies present on the conjunctiva or cornea can be easily detected and removed, and may not cause much harm if treated appropriately without delay. Subconjunctival foreign bodies are relatively rare, commonly missed and present as foreign body granuloma, even if they are visible their extent in deeper tissue is difficult to assess. Foreign bodies penetrating the ocular coat can result in partial or full thickness penetration of the cornea and sclera with or without involvement of the posterior segment.

Here we present a case of subconjunctival metallic foreign body embedded in deeper sclera in a 22-year-old male working in a factory. The foreign body was removed carefully under local anaesthesia, avoiding further damage to the eye. Ocular foreign body injury with suspected intraocular penetration, needs immediate ophthalmology consultation. Early referral to an ophthalmologist in well-equipped specialised centres is recommended in ocular trauma with suspected intraocular penetration to achieve a good visual outcome and avoid further complications like in this case.

Biography

Dr. Suwarna Suman is an assistant Professor of ophthalmology, All India Institute of Medical Sciences Jodhpur, India. She received MBBS and MS degrees in Ophthalmology from GSVM Medical College, Kanpur, India. She has authored several ophthalmic research publications, book chapters, and serves as a reviewer for peer-reviewed international ophthalmology journals. She is specialised in oculoplastic surgery including cosmetic and reconstructive eyelid surgery, orbital reconstructive surgery and lacrimal surgery.

3rd Global Ophthalmology and Eye Diseases Summit



Eye disorders spectrum: A tertiary hospital pediatric ophthalmology clinic based in Ethiopia

Yohannes Tewolde Kidane and Addisu Worku Teshome
Department of Ophthalmology, Addis Ababa University, Ethiopia

Background: Epidemiological studies to determine the pattern of eye disorders among children are important for proper health care planning and management. This study aimed to document the spectrum and frequency of eye diseases in children who attended the pediatric ophthalmology clinic of a tertiary teaching hospital in Addis Ababa, Ethiopia.

Methods: A cross-sectional and convenient sample of 1237 male and female children (16 years and below) with ocular disorders presenting for the first time and those children with a settled diagnosis coming for a follow-up visit between June 1, 2018, and May 31, 2019, were included in the study. Data on presentation age, sex, and diagnosis were collected and analyzed. Eye disorders were classified into various categories. Children were grouped into four age groups. Ratios, percentages, and chi-square associations were calculated. $P < 0.05$ was considered statistically significant.

Results: Of the children, 60% were male. The

mean age (standard deviation) of the children was 4.26 (± 4.1) years. Patients aged 0– < 6 years old were the largest group, constituting 70.5%. Ocular motility imbalances were the most common ocular disorders seen (32.8%), followed by childhood cataract (18.4%) and infection and inflammation of the eye and adnexa (8.3%). Ocular motility imbalances were observed more frequently and statistically significantly ($p < 0.001$) in children aged 1– < 6 years. Within the childhood cataract category, congenital cataracts were more prominent (7.1%). Within the infection and inflammation category, corneal/scleral infections were more common (3.7%).

Conclusions: The study highlights common eye disorders seen in children in a specialized hospital ophthalmic clinic. Ocular motility imbalance, childhood cataracts, infection and inflammation of the eye and adnexa were the most commonly occurring disorders. Early presentation was common, and males were more affected than females.

Biography

Yohannes Tewolde Kidane is an assistant professor and head of the ophthalmology department and working as a general ophthalmologist in Wolaita Sodo University College of Health Science and Medical Referral Hospital in Ethiopia. He received his MD in ophthalmology from Addis Abeba University College of Health Science in 2020.

He teaches and mentors undergraduate students and gives regular in-service training to staff members, doing in-base services like ophthalmic surgeries and regular ophthalmic case follow-ups. In addition, he is also involved in high volume cataract surgeries and outreaches mainly organized by the Himalayan cataract project and light for the world, which are two main foreign organizations that are actively participating in Ethiopia to reduce blindness.



Error-free and mean value based reversible data hiding using gravitational search algorithm in encrypted images

N. Amutha Prabha and K.Upendra Raju

School of Electronics Engineering, VIT University, India

In recent years, the data hiding in encrypted image is a significant topic for data security. Due to its ability to preserve the confidentiality Reversible Data Hiding (RDH) in the encrypted domain will be useful in cloud computing as an emerging technology. In this paper, an error free and mean value based RDH method with high capacity in encrypted images is proposed. Here, the image provider (content owner), data hider and data receiver are the three parties. Initially the image provider preserves the averages to get the modified image. Further encrypt the modified image with the help of encryption key and passes it to the data hider. In the data hider, Gravitational Search Algorithm (GSA) is utilized to find the best pixel locations in encrypted

image for information hiding. Moreover, with the same size of encrypted image an alpha channel is created and then combines the encrypted image and alpha channel to embed secret data to make encrypted image with embedded data. At the receiver side, with the help of encryption key the receiver recover the image by decrypting the encrypted image and also the secret bits are extracted with the help of data hiding keys by data extraction. Experimental result demonstrates that our proposed method outperforms better when compared with other state of art approaches. Also, the PSNR performance of proposed method is better of 8.36% and 18.3% when compared with other existing works.

Biography

N. Amutha Prabha completed her undergraduate in engineering (Electronics and Communication Engineering) and Masters in Applied Electronics. Received her Doctorate in Wireless communication from Anna University. Her teaching experience is about 26 years. She published more than 45 publications in an International / National Journals and conferences. Her area of interest includes Wireless/Mobile Communication, Signal / Image processing and Biomedical engineering.

3rd Global Ophthalmology and Eye Diseases Summit

Visual impairment and its predictors among people living with type 2 diabetes mellitus at Dessie town hospitals, Northeast Ethiopia: Institution-based cross-sectional study

Mohammed Abdu Seid¹, Adugnaw Ambelu²,
Mengistie Diress², Yigizie Yeshaw², Yonas Akalu²
and Baye Dagne²

¹Department of Biomedical sciences, Debre Tabor University, Ethiopia

²Department of Human Physiology, University of Gondar, Ethiopia

Visual impairment is a functional limitation of the eye(s) that results in reduced visual acuity, visual field loss, visual distortion, perceptual difficulties, or any combination of the above. T2DM is one of the common causes of visual impairment. The current study aimed to determine the prevalence and predictors of visual impairment among people living with diabetes at Dessie town Hospitals, Northeast Ethiopia.

Institution based cross-sectional study was carried out, and SRS was applied to recruit study participants among type 2 diabetes. Visual impairment was measured using visual acuity test. We used Epi Data 3.1 and SPSS version 22 for data entry and statistical analysis, respectively. Both binary and multivariable logistic regression to identify statistically associated factors of visual impairment. The degree of association was determined using adjusted odds ratio with 95%CI. In the final model, statistical significance was declared at $p < 0.05$.

The current study findings revealed that the prevalence of visual impairment was 37.58%. Age, poor regular exercise, duration of DM above 5 years, insulin treatment, and poor glycemic control were statistically associated with visual impairment.

In conclusion, The proportion of visual impairment in Dessie town hospitals accounted for more than a third of patients living with T2DM. Visual impairment is associated with increased age, poor regular exercise, longer duration of DM, and insulin treatment. Thus, early detection of VI through screening and regular follow-up is recommended to reduce the risk of VI and vision loss.

Table 1: Multivariable binary logistic regression analysis for associated factors of visual impairment among people living with T2DM at Dessie town Hospitals, Northeast Ethiopia, 2020 (n=322)

3rd Global Ophthalmology and Eye Diseases Summit

Variables	Categories	VI		COR (95% CI)	AOR(95% CI)
		No	Yes		
Sex	Male	119	56	1	1
	Female	82	65	1.68 (1.06, 2.65)	1.29(0.56, 2.96)
Marital status	Unmarried	27	4	1	
	Married	174	117	4.54(1.54, 13.31)	1.25(0.30, 5.11)
Education	Unable to read and write	32	41	1	1
	Primary (1-8)	52	32	0.48 (0.25, 0.90)	0.92 (0.33 2.50)
	Secondary	51	28	0.43 (0.22, 0.82)	1.11 (0.37, 3.29)
	Diploma and above	66	20	0.23 (0.12, 0.46)	0.67 (0.20, 2.23)
Occupation	Government worker	52	18	1	1
	Private worker	81	34	1.21 (0.62, 2.36)	0.80 (0.34, 1.88)
	Farmer	23	14	1.75 (0.74, 4.12)	0.35(0.10, 1.17)
	House wife	26	34	3.77 (1.80, 7.92)	1.54 (0.59, 4.00)
	Other	19	21	3.19 (1.40, 7.25)	1.33(0.42, 4.17)
Residence	Urban	166	83	1	
	Rural	35	38	2.17(1.27, 3.68)	1.85(0.71, 4.80)
Regular-exercise	Good	94	29	1	
	Poor	107	92	2.78(1.68, 4.59)	2.91(1.47, 5.76)**
Duration of diabetes	≤5 years	154	43	1	
	>5-24 years	47	78	28.59(3.68, 221.75)	2.42(1.24, 4.73)**
Treatment	OHA without insulin	140	61	1	
	Both of OHA and insulin	34	39	2.63(1.52, 4.56)	1.45(0.71, 2.97)
	Insulin only	2	20	22.95(5.20, 101.25)	14.05(2.72, 72.35)**
Hypertension	Yes	51	47	1.86(1.15, 3.03)	1.26(0.65, 2.44)
	No	150	74	1	
Glycemic-control(FPG)	<152 (good)	94	41	1	
	≥152 (poor)	107	80	1.71(1.07, 2.73)	2.17(1.13, 4.14)*

Biography

I'm Mr. Mohammed Abdu Seid, a lecturer and young researcher at Debre Tabor University in Ethiopia with a master's degree in medical physiology since 2017. I've also done community service, community problem identification and research in addition to lecturing. I am a young scholar who has published in more than ten international reputed peer-reviewed journals.



Inadvertent intralenticular Ozurdex removal

Madhurima Roy¹ and Sagnik Surya Das.²

¹*Susrut Eye Foundation and Research Centre, India*

²*OptiSight Eye Hospital, India*

With time the number of patients undergoing intravitreal injections has grown exponentially, hence increasing the risk of accidental trauma to the lens. A 45 year old non-hypertensive, non-diabetic male who had a history of receiving an intravitreal Ozurdex (Dexamethasone) implantation for macular edema due to branched retinal vein occlusion (BRVO) in the left eye elsewhere, came to us three months following the injection with painless, gradual diminution of vision in the same eye. Visual acuity was 20/20 and 20/120 in right eye and left eye respectively. Slit lamp examination revealed posterior lenticular opacification with associated nuclear sclerosis and the Ozurdex implant was visible inside the crystalline lens. Posterior capsule status was not

discernible on the slit lamp. Intraocular pressure was within normal limit. Optical coherence tomography (OCT) showed no macular edema with maintained foveal contour. B scan revealed loss of convexity of the posterior capsule, with a cluster of echoes in the vitreous cavity immediately posterior to the posterior capsule. We report a case of accidental injection of Ozurdex into the crystalline lens and removal of the implant with low parameter phacoemulsification, removal of the Ozurdex implant, placement of three piece intraocular lens (IOL) in the sulcus and vitrectomy of dropped lens matter which occurred through pre-existing posterior capsular rent which was noted during phacoemulsification, in the same sitting.

Biography

Dr. Madhurima Roy completed her basic medical education and internship from North Bengal Medical College: 2008- 2013, followed by her residency in Ophthalmology from Aligarh Muslim University: 2015-2018. She did two fellowships, a 1 year vitreo-retina fellowship from C.H. Nagri Eye Hospital, Ahmedabad: 2018-2019 and 2 years vitreo-retina fellowship from Susrut Eye Foundation and Research Centre, Kolkata: 2020-2021, before joining as assistant professor in the same institute. Her areas of interest are surgical retina for diabetic retinopathy, macular diseases. She has several papers to her credit published in indexed journals. She is a fellow of the International Council of Ophthalmology (FICO-2019, Edinburg) and also a fellow of All India Collegium of Ophthalmology (FAICO-2021, AIOS, India). She is an active member of All India Ophthalmology Society (AIOS M19413), Vitreo Retina Society of India (VRSI M1071) and Ophthalmic Society of West Bengal (OSWB M1306).



A rare combination of complication of Ruptured aneurysm of the subclinoid portion of the internal carotid artery: Case

Zineb Boukhal Zerouali, Aicha Merzem, Amine Najmeddine, Hasna Belgadir, Omar Amriss, Nadia Moussali and Naima El Benna
Department of Radiology, Ibn Rochd University, Morocco

Introduction: The giant aneurysm of the subclinoid portion of the internal carotid artery is a relatively rare disease which can present serious complications.

Patient and methods: We report the case of a 40-year-old man complaining of headache with complete ophthalmoplegia of the right eye.

A brain scan shows a right temporal subdural hematoma, associated with subarachnoid hemorrhage, and total sylvian subacute

ischemic stroke. CT angiography and MRI show a ruptured and partially thrombosed aneurysm of the subclinoid portion of the right internal carotid artery complicated by subarachnoid hemorrhage, a right subdural temporal hematoma, and total sylvian ischemic stroke.

Conclusion: To recognize the possibility of an aneurysmal rupture when evaluating an acute subdural hematoma, alone or in combination with Ischemic stroke.



Analysis on the correlation between long-term refractive regression and visual quality after FS-LASIK

MY Zhang, X Li and QJ Hu

Ophthalmology Department, Civil Aviation Medical Center, China

Objectives: To record the long-term visual quality after FS-LASIK and analyze the effect of long-term refractive regression after corneal laser surgery on the visual quality.

Methods: Included data from 78 aircrews (153 eyes, 32 pilots and 46 flight attendants) who had undergone FS-LASIK more than 5 years before and follow-ups at Civil Aviation Medical Centre between 2020 and 2021. Collected age of surgery, postoperative period, and preoperative diopters. Pentacam measured anterior/posterior corneal curvature (ARC/PRC) and thinnest pachymetry (THP). OPD Scan measured UCVA, total corneal aberrations (CTRmsTotal), corneal higher order aberrations (CTRmsHO), total ocular aberrations (RmsTotal), total ocular higher order aberrations (RmsHO), total ocular modulation transfer function (MTFTotal), higher order modulation transfer function (MTFH0), total ocular point spread function (PSFTotal), corneal point spread function (PSFH0), total Coma (Coma-T) corneal Coma (Coma-CT), total spherical aberration (SA-T), corneal spherical aberration (SA-CT), Total Trefoil (Trefoil-aT) and corneal Trefoil (Trefoil-

CT). We allocated the aircrew into emmetropia ($SE \leq -0.5D$) 40 cases (78 eyes) and regression ($SE > -0.5D$) 38 cases (75 eyes) groups based on their postoperative diopters.

Results: The values for postoperative periods, CTRmsTotal, CTRmsHO, and RmsTotal, Coma-CT, CTSA-CT in the emmetropia group were significantly lower than those in the regression group. The age of surgery, UCVA, MTFTotal, MTFHO, PSFTotal, and CTPSF values in the emmetropia group were significantly higher than those in the regression group. The preoperative diopters, ARC, PRC, THP, RmsHO, Coma-T, SA-T, Trefoil-T and Trefoil-CT values were similar in both groups. The postoperative diopter value was significantly correlated with age of surgery, postoperative period, THP, MTFTotal, PSFTotal, Coma-T, and SA-CT.

Conclusion: After FS-LASIK, young patients with relatively thin corneas are susceptible to refractive regression. With the extension of postoperative period, refractive regression may aggravate. There was no significant correlation between postoperative refractive regression and higher order aberrations.

Biography

Mingyue Zhang, PhD/OD, Civil aviation medical center of China, designated AME of CAAC. Ophthalmology and Optometry Specialties □ Refractive surgery and Medical assessment of civil aviation aircrews. Research Interests: corneal biomechanical properties, Visual function and safety capability of civil aviation pilots.



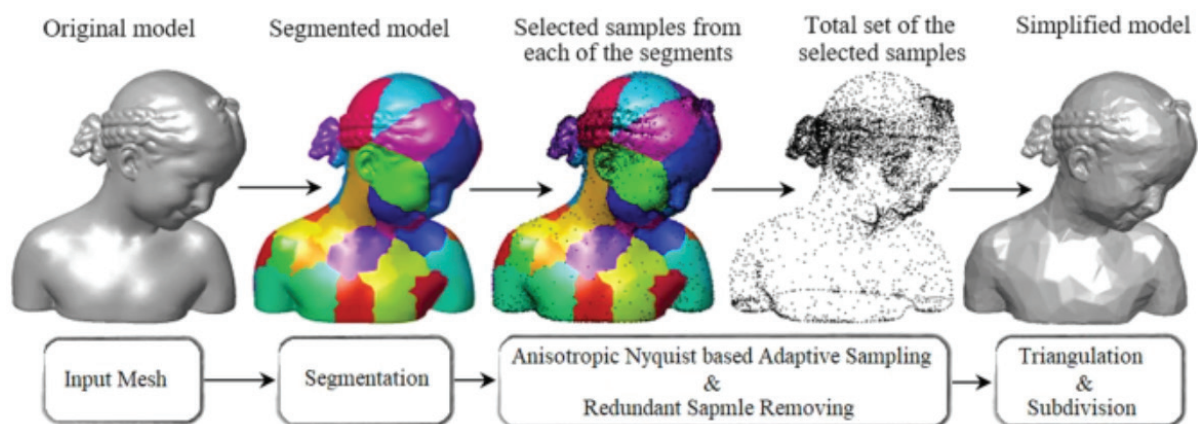
Feature preserving mesh simplification through anisotropic Nyquist based adaptive sampling of points inside the segmented regions

Lida Asgharian and Hossein Ebrahimnezhad

Department of Electrical Engineering, Sahand University of Technology, Iran

Widely increasing of 3D applications for using in mobile phones and other electrical devices reveals the importance of 3D mesh representation. Since visualization and implementation of a coarse and simplified mesh is easier than analyzing a high resolution mesh, the simplified mesh is preferred for processing. In this paper, a new 3D mesh simplification method is presented to simplify a mesh by anisotropic Nyquist based adaptive sampling of each segmented region on the surface. Since the sampling step is completed for each segmented region individually, the algorithm can preserve the sharp features of each segment, precisely.

The least number of samples is selected from each segment based on its details. Adjusting the sampling procedure according to the geometrical features of the mesh leads to accurately approximate the overall shape of the original model. In order to connect the selected samples, the original mesh connections are employed to better maintain the structure and shape of the input mesh. The experimental results show the ability of the proposed method in preserving important features of different complex meshes. The simplified models can be efficiently reconstructed based on the selected samples of each region.



Biography

Lida Asgharian received her MSc and PhD degrees in Electronic and Communication Engineering from Sahand University of Technology, Iran in 2014 and 2021, respectively. Her research topics include computer graphics, computer vision, machine learning, 3D model simplification, 3D reconstruction and animation.

3rd Global Ophthalmology and Eye Diseases Summit



Fixational eyes movements: Hopf bundle, Listing's law, and a model of saccadic cycle

Dmitri Alekseevsky¹ and Ilya Shirokov²

¹Institute for Information Transmission Problems Moscow, Russian Academy of Sciences, Russia

²Steklov Mathematical Institute of Russian Academy of Sciences, St-Petersburg, Russia

The eyes are never in still. Even when the gaze is fixed, the eyes participate in fixation eye movements : tremor, drift and microsaccades

We shortly describe the basic properties of fixation eye movements and their role in vision.

Eye movements are governed by the laws of Donders and Listing. Donders' Law states that when the head is fixed the configuration space of the eye is two-dimensional that is the gaze determines the eye position (no twist). The Listing's law specifies the eye position.

We propose an interpretation of Listing's law in terms of the Hopf fibration. We identify the configuration space of the eye ball (when the head is fixed) with the 2-dimensional unit hemisphere S^2_L , called Listing hemisphere. The Hopf map associates the gaze direction $A \in S^2_E$ to an eye position $a \in S^2_L$, where $S^2_E \subset R^3 = \text{span}(i,j,k)$ is the primary eye position such that i is the gaze direction.

The saccade between position $a, b \in S^2_L$ is the geodesic ab of the Listing's hemisphere (with respect of the standard metric) and its image under the Hopf map is the segment AB

of the circle S^1 which is the section of the eye sphere by the plane through $A, B, -i$.

Each saccade ab is realized by a rotation R_{ω}^{ϕ} around some axis $\omega \in S^2_E$ on some angle ϕ and it is accompanied by presaccadic remapping from coordinate frame a to b (which are completely determined by a, b).

The vision is the result of interaction on stochastic information which comes to the retina during drift with information about saccadic rotation R_{ω}^{ϕ} around an axis ω by an angle ϕ , which produce the remapping and is coded into oculomotor system.

We consider an n -cycle which consists of n consecutive microsaccades $a_{j-1}a_j$, alternating with n drift and describe the relations between the gaze direction a_j of j -th saccade $a_{j-1}a_j$ and the corresponding axis of rotations ω_j . We shortly discuss the diagnostic value of saccades in movement disorder and the role of the studies of saccadic abnormalities in understanding the neural control of saccades.



3rd Global Ophthalmology and Eye Diseases Summit

Biography

Dmitri Alekseevsky has PhD and Doctor Degree in Mathematics,
 He is a Leading Researcher in Institute for Information Transmission Problems 2011-,,
 Emeritus Professor of Hull University (UK) , 2005-,,
 a member of Edinburgh Mathematical Society,
 an editor of the journals
 "Differential geometry and its Applications " 1989- , "Transformation Groups",1995-,,
 "International J. of Geometric Methods in Modern Physics" 2003-/
 He was a Chief Researcher in Scientific Center "Sophus Lie " (1990-2000) Moscow,,
 Chair in Pure Mathematics at Hull University (2000- 2005), Visiting Professor of Edinburgh
 University 2005-2009, Visiting Professor of Brno University (2011-2014).

The main subjects of his interest are

Differential Geometry, Lie Groups and their Applications to Mathematical Physics and Neuroscience: Riemannian and pseudo-Riemannian Geometry, Spinor Geometry, Homogeneous Spaces, Transformation Groups, Differential Geometry and PDE, Geometric Structures on Manifolds, Holonomy Groups and Special Geometry, Generalized Geometry, General Relativity, Yang-Mills Fields, Supergravity, Information Geometry, Applications of Differential Geometry to Neuroscience (Neurogeometry) D. Alekseevsky published more then 160 papers



Improvement of eye dosimetry: The application of photon beam radiotherapy in patients with eye melanoma

M. Živković¹, T. B. Miladinović², M. Ž. Radojević,
N. Milosavljević, D. Krstić¹ and A. M. Miladinović⁴

¹Institute of Physics, University of Kragujevac, Serbia

²Institute for Information Technologies, University of Kragujevac, Serbia

³Centre for Radiation Oncology, University Clinical Centre Kragujevac, Serbia

⁴University Clinical Center Kragujevac, Medical Physics Department, Serbia

The main objective of this paper is therefore to illustrate the potential of the programs in the treatment of the eye melanoma. FOTELP-VOX is voxelized geometry Monte Carlo transport algorithm based on CT data. The exponential growth of computer capabilities in the first decade of the XXI century and with it the development of models for simulation of physical processes in particle transport further favored the use of Monte Carlo techniques in radiotherapy. The predictions of medical physicists that the

programs for radiotherapy planning will enter clinical practice are becoming validated.

A CT scan of the patient's head was used, with voxel sizes of 0.5 mm, 0.5 mm, and 1.0 mm. The melanoma was thought to be spherically formed and located at the bottom of the eye. A therapy plan was created using FOTELP-VOX software and a 1 cm radius cylindrical photon beam with a mean energy of 6 MV. A total of 109 photon histories were used in the simulation (fig 1.).

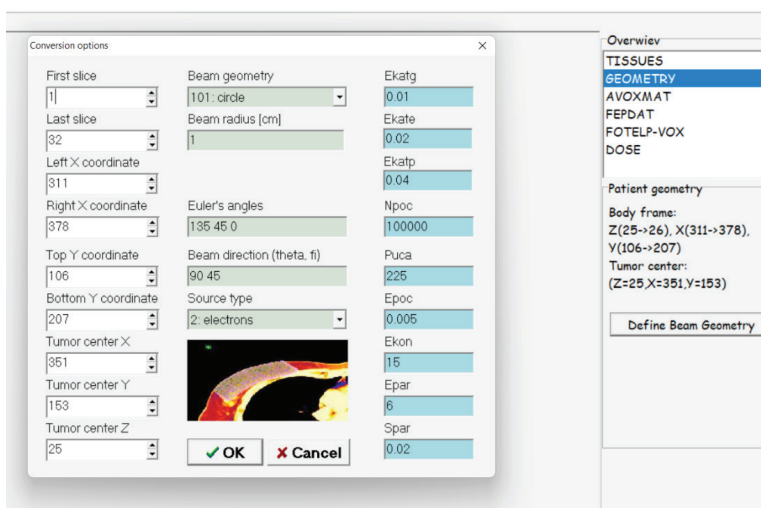


Figure 1. Appearance of the VOXVIEW program interface.

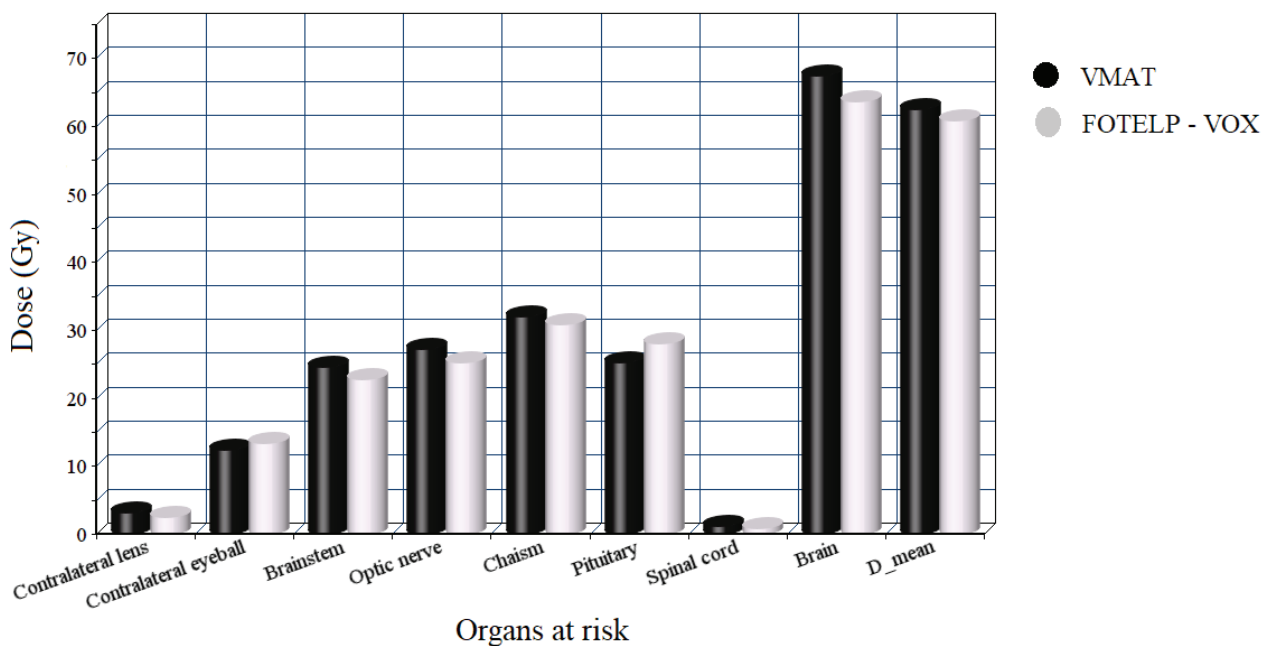
3rd Global Ophthalmology and Eye Diseases Summit

The radiation oncologist contoured OARs (Organ At Risk) right lens, right eyeballs, optic nerves, optic chiasm, pituitary, brain, and brainstem. The aim of treatment planning was to optimize coverage of at least 95 % of PTV with 95% of the prescription dose and provide maximum protection of organs at risk. The prescription was normalized to 60 Gy at 30 fractions at 6 MV and two full arcs VMAT plan was generated for the patient using the ECLIPSE version (15.6) (Varian Medical Systems, Palo Alto, CA).

FOTELP-VOX and VMAT meet the clinical

requirements, and they are compromised so that other OARs like the brain also meet the requirements (graph 1.). The absorbed doses were determined, with the difference between these two techniques ranging from 3.2 to 27.0%

The VMAT approach can be used to create a radiation strategy for the treatment of intraocular cancer. VMAT gave a minimal dose to the contralateral lens and eyeballs while achieving high uniformity and conformity for the target volume. However, it increased the low dose volume of the OARs.



Graph 1. VMAT and FOTELP-VOX delivery parameters and mean dose in target tumor.

Biography

Milena P. Zivkovic was born in Kragujevac on September 1, 1995. In the 2018/2019 academic year, she completed her undergraduate studies with a 9.49 average. She was named the best student at the Faculty of Sciences and Mathematics for four years in a row. She continues her education at the Faculty of Natural Sciences and Mathematics in Kragujevac, within the Institute of Physics, in 2018 at the academic master's studies, majoring in physics, average grade (9.67). She is currently a doctoral student of physics. Since January 2020, she has been employed at the Institute of Physics, as a junior researcher. So far, she has participated in the implementation of the project of the Ministry of Education: "Experimental and theoretical research in radiation physics and radioecology". So far, she has published 15 papers, 5 of which are from the SCI list. The doctoral dissertation includes the use of voxelization in radiotherapy.

3rd Global Ophthalmology and Eye Diseases Summit

Microvascular complications and its predictors among type 2 diabetes mellitus patients at Dessie town Hospitals, Ethiopia

Mohammed Abdu Seid¹, Yonas Akalu², Yibeltal Yismaw Gela², Yitayeh Belsti², Mengistie Diress², Sofonias Addis Fekadu³, Baye Dagne² and Mihret Getnet²

¹Department of Biomedical science, Debre Tabor University, Ethiopia

²Department of Human Physiology, University of Gondar, Ethiopia

³Department of Optometry, University of Gondar, Ethiopia

Objectives: Diabetes mellitus is a significant metabolic illness that has been increasingly prevalent in middle and low-income countries during the last few decades. Retinopathy, neuropathy, and nephropathy are all microvascular consequences that can cause disability, reliance, and increase morbidity and death. There is a scarcity of data on this topic in Ethiopia. Hence, the goal of this study was to determine the prevalence of microvascular problems and their determinants among type 2 diabetes patients.

Methods: A cross-sectional study was undertaken in Dessie town hospitals from February to March 2020. To enroll study participants, we employed simple random sampling and a pre-tested interviewer-administered questionnaire. For analysis, data was imported into Epi-Data 3.1 and exported to SPSS - 23. At $p < 0.05$, binary logistic regression was used to select potential factors for adjustment. Variables having a p-value of less than 0.05 were judged statistically significant after running multivariable regression.

Results: The study included 335 type 2

diabetes patients, with males accounting for 54.6% of the total. One hundred and twenty-seven people with diabetes mellitus [37.9% (95% CI: 32.5 percent -43.3 percent)] had at least one microvascular problem. Retinopathy accounted for 24.8 percent, nephropathy 16.1 percent, and neuropathy 8.1 percent of the total. There were statistically significant associations between age 60-87 years (AOR=2.76, 95% CI: 1.02-7.46), diabetes duration > 5 years (AOR=4.09, 95% CI: 2.40-6.96), and diabetes and co-morbid hypertension (AOR=3.52, 95% CI: 2.09-5.95).

Conclusions: Diabetic microvascular problems are common in this study. Participants' age, the duration of their diabetes, and co-morbid hypertension were all independent predictors. Early detection and care of microvascular complications should be emphasized by health providers, as should early screening and health education, abrupt medication for elderly individuals with long-term diabetes, and hypertension.

3rd Global Ophthalmology and Eye Diseases Summit

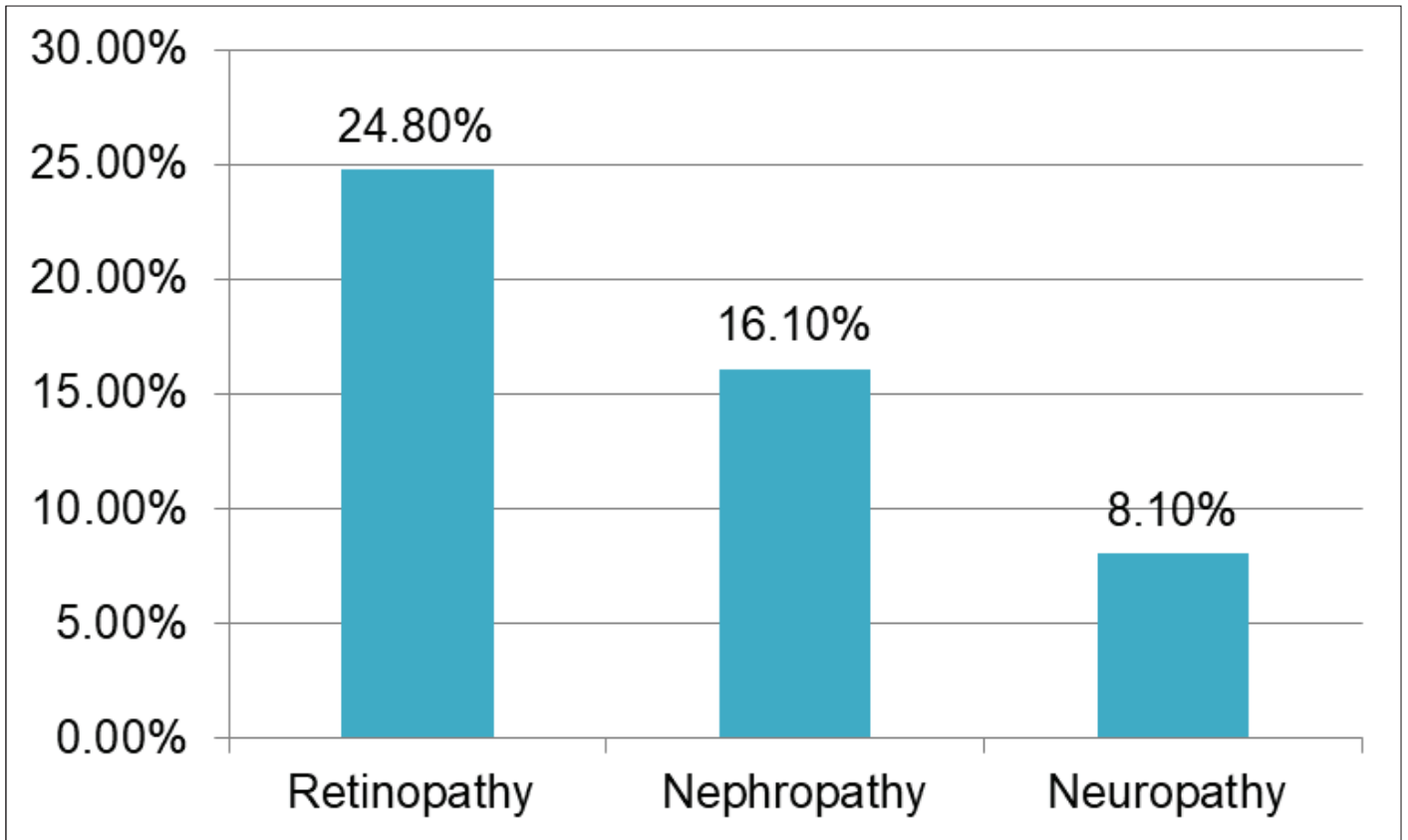


Figure 1: Proportion of micro-vascular diabetic complications among type-2 diabetes mellitus at Dessie City Hospitals, Ethiopia 2020

3rd Global Ophthalmology and Eye Diseases Summit

Table: Multivariable binary logistic analysis for factors associated to micro-vascular complications among type-2 diabetes mellitus at Dessie City Hospitals, Ethiopia 2020 (n=335).

Parameters	Categories	% of complication		of OR	
		No	Yes	COR (99% CI)	AOR(95%CI)
Age	20-39 years	30	7	1	1
	40-59 years	139	56	1.72(0.71-4.16)	1.18(0.46-3.01)
	60-87 years	39	64	7.03(2.82-17.54)	2.76(1.02-7.46)*
Marital status	Never married	24	9	1	1
	Married	184	118	1.71(0.76-3.80)	0.72(0.24-2.11)
Residence	Urban	174	85	1	1
	Rural	34	42	2.52(1.50-4.25)	1.68(0.68-4.11)
Education	No read and write	31	47	1	1
	Grade 1-8	53	31	0.38(0.20-0.72)	0.63(0.27-1.46)
	Grade 9-10	59	23	0.25(0.133-0.45)	0.46(0.17-1.20)
Occupation	Certificate and above	65	26	0.26(0.14-0.50)	0.54(0.20-1.46)
	Employed	49	24	1	1
	Private worker	83	34	0.83(0.44-1.57)	0.53(0.23-1.24)
	Peasants	18	19	2.15(0.96-4.83)	0.28(0.07-1.09)
	House wife	34	31	1.86(0.93-3.70)	1.15(0.44-2.99)
Duration of T2DM	Other	24	19	1.61(0.74-3.50)	0.37(0.12-1.101)
	≤ 5 years	160	45	1	1
Medication regimen	>5 years	48	82	6.07(3.73-9.87)	4.09(2.40-6.96)**
	Drugs (OHA)	158	65	1	1
	Mixed(oral & insulin)	40	44	2.67(1.59-4.48)	1.24(0.56-2.390)
Hypertension	Insulin only	10	18	4.37(1.91-9.98)	2.35(0.82-6.66)
	No	150	81	1	1
Physical activity	Yes	58	46	4.93(3.06-7.95)	3.52(2.09-5.95)**
	Good	87	40	1	1
Adherence	Poor	121	87	1.56(0.98-2.48)	0.93(0.50-1.72)
	No	46	20	1	1
	Yes	162	107	1.51(0.85-2.71)	1.17(0.55-2.47)

Biography

I am Mr. Mohammed Abdu Seid, MSc in Medical Physiology, lecturer and researcher at Debre Tabor University, College of Medicine and Health science, Ethiopia. I have also participated in community service and research alongside with lecturing. I am young researcher having more than 11 publications in international peer reviewed journal. More than 10 international journal publishers accredited me for article reviewing

3rd Global Ophthalmology and Eye Diseases Summit



Combat-related ocular injuries in the Israel Defense Forces during the years 2013 to 2019

N. Shakarchy-Kaminsky¹, J. Megreli¹, Dan Kaminsky¹, Avishai M Tsur^{1,2}, Roy Nadler^{1,3}, Irina Radomislensky¹, Shaul Gelikas¹, Elon Glassberg^{1,4,5}, Avi Benov^{1,4} and Ariel Furer¹

¹Israel Defense Forces Medical Corps, Israel

²Department of Medicine 'B', Sheba Medical Center, Tel Hashomer, Ramat Gan, Israel; affiliated to Sackler Faculty of Medicine, Tel Aviv University, Israel

³Department of General Surgery and Transplantation-Surgery B, Chaim Sheba Medical Center, Tel Hashomer, Affiliated to Sackler School of Medicine, Israel

⁴The Azrieli Faculty of Medicine, Bar-Ilan University, Israel

⁵Uniformed Services University of the Health Sciences, Maryland

Background: Ocular injuries account for up to 13% of battle injuries, despite the implementation of advanced protective eyewear (PE). The aim of this study was to describe the extent of ocular injuries over the last years among Israel Defense Forces soldiers and to examine the change in PE policy introduced in 2013 and the effect of a high-intensity conflict on ocular injury characteristics.

Methods: This retrospective registry-based analysis derived data from the Israel Defense Forces Trauma Registry and included soldiers who sustained combat-related ocular injuries between the years 2013 and 2019. Demographic data and injury characteristics of casualties, as well as information regarding the use of PE, were collected and analyzed.

Results: A total of 2,312 military casualties were available for this study; the incidence of combat-related ocular injuries was 8.9% (n = 113). Ocular injuries occurred among male

soldiers (98.2%) with a mean \pm SD age of 22.7 ± 4.6 years; mechanism of injury was penetrating in 59.3% of the casualties and blunt in 22.1% of the casualties, ocular injury was isolated in 51.3% of the casualties, and others sustained concomitant injuries including head (32.7%), upper extremity injury (17.7%), lower extremity (15.9%), torso (8.0%), neck (6.2%), and other (5.9%) injuries. Ocular injuries rate was similar among casualties who used PE (11.2%) and those who did not use PE (13.0%) while injured (p = 0.596). Rate of open globe injuries was 9.1% in casualties who used PE and 39.5% (p = 0.002) in casualties who did not.

Conclusions: Eye protection may significantly reduce ocular injuries severity. Education of the combatants on the use of PE and guidance of medical teams on proper assessment, initial treatment, and rapid evacuation of casualties are needed to improve visual outcomes of the casualties further.

3rd Global Ophthalmology and Eye Diseases Summit

TABLE 4. Visual Outcomes of Casualties Sustaining Ocular Injuries

	Casualty Used PE (n = 14)	Casualty Did Not Use PE (n = 47)	Total (n = 61)	<i>p</i>
Classification of ocular injury*				
Open globe	1 (9.1%)	17 (39.5%)	18 (33.3%)	0.002
Closed globe	10 (90.9%)	14 (32.6%)	24 (44.4%)	
Chemical	0 (0.0%)	12 (27.9%)	12 (22.2%)	
First postinjury BCVA**				
20/200 or worse	1 (50.0%)	5 (35.7%)	6 (37.5%)	1.000
20/160–20/50	0 (0.0%)	0 (0.0%)	0 (0.0%)	
20/40 or better	1 (50.0%)	9 (64.3%)	10 (62.5%)	
Last post-injury BCVA†				
20/200 or worse	1 (16.7%)	6 (19.4%)	7 (18.9%)	1.000
20/160–20/50	0 (0.0%)	0 (0.0%)	0 (0.0%)	
20/40	5 (83.3%)	25 (80.6%)	30 (81.1%)	

*Missing values, 7 (11.5%).
 **Missing values, 45 (73.8%).
 †Missing values, 24 (39.3%).

Biography

My name is Nitzan Shakarchy-Kaminsky, M.D. and M.Sc. graduate from the Hebrew University in Jerusalem, Israel. I currently serve in the IDF (Israel Defense Forces) as a military doctor, and will specialize in ophthalmology next year when I finish my service. As a military doctor I take part in academic research in various fields, including mainly ophthalmology, in order to learn and improve knowledge and medical care guidelines in those fields. The IDF epidemiological as well as trauma care research is based on unique databases which consists of millions of records collected over years. I am honored to offer my participation and share our conclusions.



Impact of visual field loss post-stroke on activities of daily living: A prospective cohort study

Christian Garcia¹, Ronan Collins¹, Dominick McCabe^{1,2,3,4},
 Rose Galvin^{5,6} and Pauline Boland^{5,6}

¹Tallaght University Hospital, Ireland

²Department of Neurology and Stroke Services, Tallaght University Hospital, Ireland

³Department of Clinical Neurosciences, Royal Free Campus UCL Queen Square Institute of Neurology, U.K

⁴Academic Unit of Neurology School of Medicine, Trinity College Dublin, Ireland,

⁵School of Allied Health, University of Limerick, Ireland

⁶Ageing Research Centre, University of Limerick, Ireland

This study investigated the ADL performances of people with VFL after an acute stroke using an observation-based evaluation of ADL skills, the Assessment of Motor and Process Skills. The AMPS was administered on initial assessment and at 11 weeks follow-up on 58 adults with a mild stroke, with (n=16) and without VFL (n=42), over a 13-month period. The AMPS guidelines on clinically relevant difference of 0.30 logits was used to determine the differences of the groups' ADL performance on initial assessment and follow-up. The study found that the

ADL motor and process scores did not differ significantly on initial assessment.

The study observed no clinically relevant difference between the ADL motor and process scores of between the VFL and non-VFL on initial assessment and follow-up but demonstrated clinically relevant improvements in ADL motor and process scores of both groups from initial assessment to follow-up. VFL does not have an additional negative impact on ADL performance of those with a mild stroke and does not impede improvement of ADL performance over time.

3rd Global Ophthalmology and Eye Diseases Summit

Table 1. AMPS motor and process ability scores in logits, including differences in scores at initial assessment and on follow-up.

Initial Assessment	VFL Group N= 16 (27.6%)	Non-VFL Group N= 42 (72.4%)	Differences (logits)
AMPS Motor Median Quartiles Min-Max	1.8 1.5 - 2.27 1.0 - 2.70	1.6 1.15 - 1.90 0.50 - 2.40	0.20
AMPS Process Median Quartiles Min-Max	0.90 0.52 - 1.0 -0.3 - 1.20	0.80 0.50 - 0.90 -0.2 - 1.30	0.10
Follow-up Assessment	N= 16/ (31.4%)	N= 35/ (68.6%)	
AMPS Motor Median Quartiles Min-Max	2.10 1.90 - 2.40 1.80 - 2.60	2.10 1.80 - 2.40 0.80 - 2.70	0.0
AMPS Process Median Quartiles Min-Max	1.10 0.90 - 1.20 0.1 - 1.50	1.10 0.80 - 1.20 0.3 - 1.60	0.0

Biography

Christian Garcia is a senior occupational therapist in the acute stroke and stroke rehabilitation services unit in Tallaght University Hospital, Dublin, Ireland. He has been working in the Health Service Executive in Ireland for the last 18 years. He has completed his master's in research dissertation from the University of Limerick on the effect of visual field loss on occupational performance. The findings of his research have been published recently in the Neuropsychological Rehabilitation Journal.

3rd Global Ophthalmology and Eye Diseases Summit



Association Between Body Mass Index and Visual Acuity in 1.6 Million Israeli Adolescents

Itay Nitzan^{1,2} and Nitzan Shakarchy-Kaminsky¹

¹Israel Defense Forces Medical Corps, Ramat Gan, Israel

²Department of Military Medicine and "Tzameret", Faculty of Medicine, Hebrew University, Israel

Background: The association between body-mass index (BMI) and visual acuity is conflicting. This study purpose was to investigate the correlation BMI and visual impairment (VI) in a national cohort of Israeli adolescents.

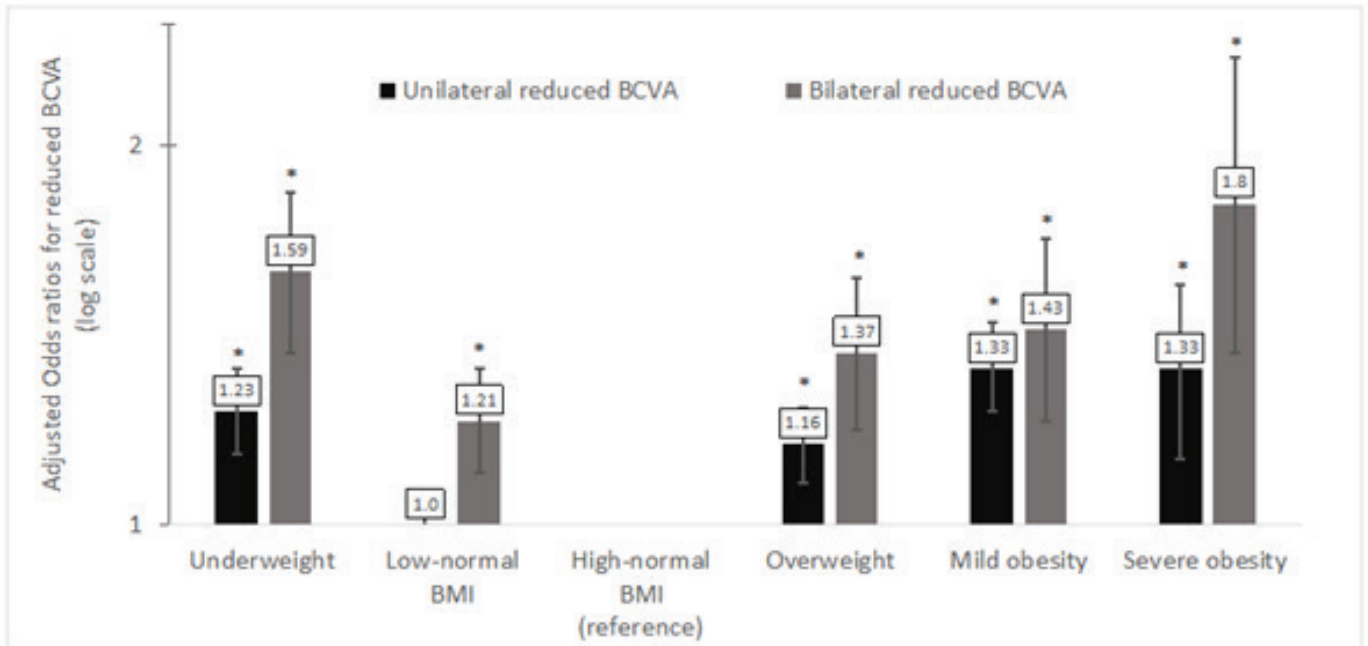
Methods: 1,697,060 participants (56.4% men) were included in this population-based cross-sectional study of Israeli adolescents aged 16-19 years old. Participants were evaluated at military recruit centers before mandatory military service between 1993 to 2017. Sociodemographic data and anthropometric measurements were obtained. BMI was classified according to the US age- and sex-matched percentiles. VI was defined using best corrected visual acuity (BCVA) measurements performed with a standard Snellen chart. Participants with a BCVA of 6/9 or better in both eyes were classified as having normal vision. Participants with a BCVA of 6/12 or worse in one or both eyes were classified as having unilateral or bilateral VI, respectively. Odds ratios (ORs) and 95% confidence intervals (CI) for VI in each BMI

category were computed for men and women using multinomial logistic regression analyses.

Results: 17,871 (1.05%) and 5,148 (0.30%) participants had unilateral and bilateral VI, respectively. Compared with high-normal BMI (reference group), adjusted ORs for unilateral and bilateral VI increased with higher BMI reaching 1.33 (95%CI 1.13-1.55) and 1.80 (95%CI 1.37-2.35) in men with severe obesity, and 1.51 (95%CI 1.24-1.84) and 1.52 (95%CI 1.08-2.14) in women with severe obesity. Underweight men also had elevated ORs for unilateral and bilateral VI (OR=1.23; 95%CI 1.14-1.33 and OR=1.59; 95%CI 1.37-1.84, respectively). Associations persisted in several sensitivity analyses, including among participants with unimpaired health.

Conclusions: Our results demonstrate an association between BMI and VI at adolescence, more evidently among young men than women. Future research should focus on underlying causes of association and address tailored health promotion initiatives directed at susceptible populations.

3rd Global Ophthalmology and Eye Diseases Summit



* $p < 0.001$

Biography

My name is Nitzan Shakarchy-Kaminsky, M.D. and M.Sc. graduate from the Hebrew University in Jerusalem, Israel. I currently serve in the IDF (Israel Defense Forces) as a military doctor, and will specialize in ophthalmology next year when I finish my service. As a military doctor I take part in academic research in various fields, including mainly ophthalmology, in order to learn and improve knowledge and medical care guidelines in those fields. The IDF epidemiological as well as trauma care research is based on unique databases which consists of millions of records collected over years. I am honored to offer my participation and share our conclusions.

ACCEPTED ABSTRACTS



Virtual Event

3RD GLOBAL

**Ophthalmology
and Eye Diseases
Summit**

September 12-13, 2022

NOVEL OPHTHALMOLOGY 2022



Prevalence of trachoma in 72 Districts of Afghanistan in 2018–2019



Ahmad Shah Salam

Ministry of Public Health, Afghanistan

Background: To determine where interventions are needed to eliminate trachoma as a public health problem, prevalence data are needed. We aimed to generate baseline population-based data on trachoma prevalence in suspected-endemic areas of Afghanistan.

Methods: Cross-sectional population-based prevalence surveys designed according to World Health Organization (WHO) recommendations were conducted in 35 evaluation units (EUs) covering 72 districts across 16 provinces were surveyed in two phases from September 2018 to December 2019. In selected households, all resident individuals aged ≥ 1 year were examined for trachomatous inflammation—follicular (TF) and trachomatous trichiasis (TT) according to the WHO simplified trachoma grading system. Water, sanitation and hygiene access was assessed in households of survey participants.

Results: 104,104 people aged ≥ 1 year were examined, including 43,774 children aged 1–9 years and 46,439 people aged ≥ 15 years. The age-adjusted prevalence of TF in 1–9-year-olds was $\geq 5\%$ in 3 EUs, with the highest EU TF prevalence being 7.8%. The age- and gender-adjusted prevalence of TT unknown to the health system in ≥ 15 -year-olds was $< 0.2\%$ in all EUs. The majority of households had access to an improved water source within 30 minutes of the house. However, only a minority of households had an improved latrine and/or a hand wash station.

Conclusions: Trachoma is not a public health problem in the majority of EUs surveyed. However, antibiotic mass drug administration, promotion of facial cleanliness and environmental improvement (the A, F and E components of the SAFE strategy) are needed for trachoma elimination purposes in three of the EUs surveyed in Afghanistan.



Artificial intelligence role on eye diseases



Ashraf ALDabbas^{1,2}

¹University of Debrecen, Hungary

²Al- Balqa' Applied University, Jordan

In the field of clinical ophthalmology, many image-related diagnostic approaches have recently started to give previously unattainable levels of insight into eye illnesses by using morphological datasets that include millions of data points. The complex neural structure of the human brain served as the inspiration for artificial intelligence (AI), which has shown astounding performance in some visual and auditory recognition tasks. When it comes to these kinds of jobs, AI is capable of doing thorough, quick, and non-invasive analyses of digital data. In the realm of medical imaging, in particular, bioinformatics has emerged as a primary area of concentration. This trend is being propelled by advances in

computing power and cloud storage, as well as the implementation of innovative algorithms and the production of data in very large amounts. The subfield of AI known as machine learning (ML) is a very significant area. In the not-too-distant future, the total capacity of machine learning to automatically detect, identify, and grade problematic aspects in ocular disorders will enable ophthalmologists to make high-quality diagnoses and will enhance the delivery of tailored health care. The purpose of this article is to provide an overview of the history, development, and uses of machine learning (ML) technology, with a specific focus on the technology's applications in ocular imaging modalities.

“
**Roberts syndrome with
 negative cytogenetic
 analysis presenting
 with bilateral congenital
 glaucoma and unilateral
 ectopic kidney; unilateral
 hand rudimentary digits:
 A case report**
 ”

Amar Almulhim, Essam A Osman, Ehab Alsirrhy and Basamat AlMoallem
King Saud University, Saudi Arabia

Objectives: We are presenting a rare case of one week old baby with Roberts syndrome associated with bilateral congenital glaucoma (Figure 1), general body system examination within normal limits except left-hand rudimentary digits (Figure 2) and right ectopic kidney. Bilateral non-penetrating glaucoma

surgery done with good control of intraocular pressure for more than six months. To the best of our knowledge, this is the first case reported with phocomelia, bilateral congenital glaucoma, and unilateral ectopic kidney without any detected genetic abnormality.

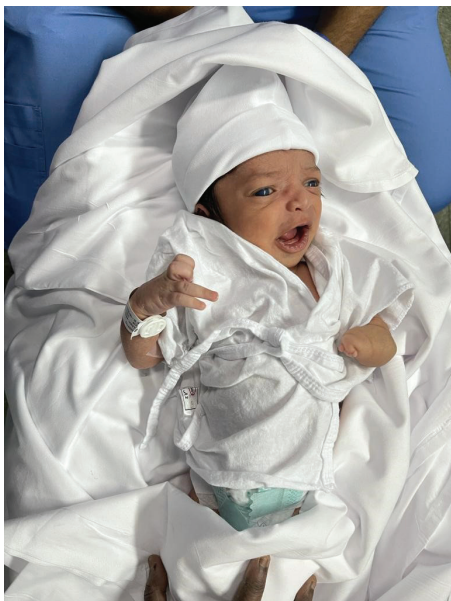

Figure 1: Bilateral buphthalmos and corneal haze

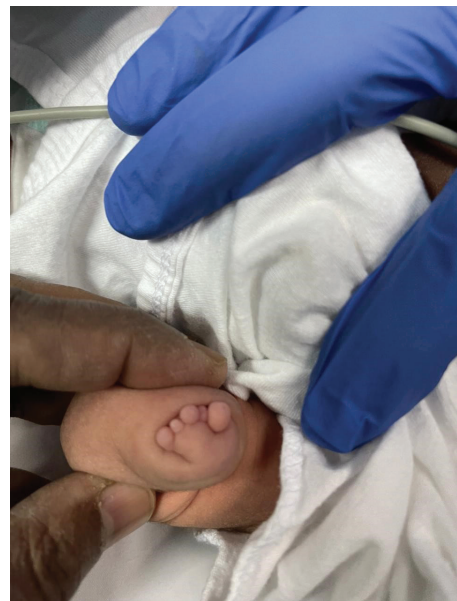

Figure 2: Left-hand rudimentary digits

3rd Global Ophthalmology and Eye Diseases Summit

Method: Case report

Results: Based on the clinical findings, the presumed diagnosis was Roberts syndrome with bilateral congenital glaucoma. Non penetrating Deep Sclerectomy plus Mitomycin C was performed for both eyes and intraocular pressure was stable for more than 6 months. Molecular analysis showed no abnormality.

Conclusion: We recommend full ophthalmic evaluation for any suspected case of Roberts syndrome to rule out any ocular involvement including congenital glaucoma to stave off any potential damage for the eye.

“ Bilateral multiple ciliary body cysts with angle-closure glaucoma in 18-year-old patient: A case report ”

Amar Almulhim

King Saud University, Saudi Arabia

Objectives: To present a rare case of an 18-year-old medically free male who presented with a history of decrease in vision in the left eye over the last 4 years. On examination, best-corrected visual acuity (BCVA) was 20/20 in the right eye (RE) and CF 3 feet in the left eye (LE). Intraocular pressure (IOP) was 34 and 40 mm Hg in the RE and LE, respectively. Fundus examination showed cupping of 0.7 on the

right and 0.9 on the left (Figure 1). Gonioscopy revealed bilateral angle-closure with plateau iris configuration. Ultrasound Biomicroscopy (UBM) showed bilateral multiple ciliary body cysts replacing ciliary body sulcus space.

Method: Case report

Results: Based on the clinical and UBM findings, a diagnosis of pseudoplateau iris

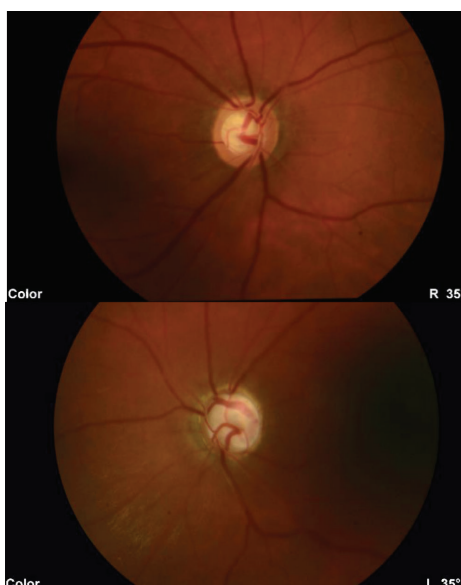

Figure 1: Color fundus showed cupping of 0.7 on the RE (upper photo) and 0.9 on LE (lower photo).

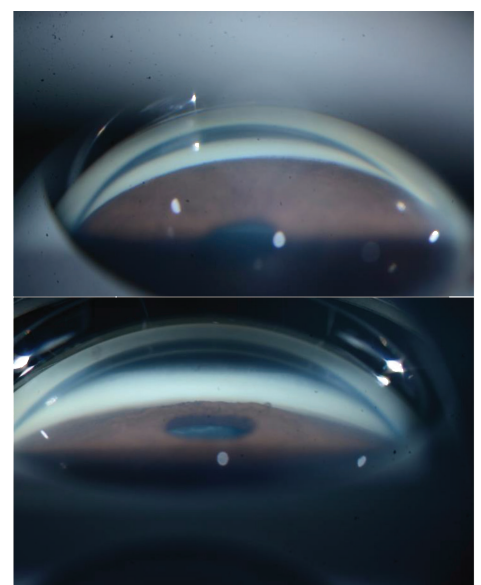


Figure 2: Gonioscopy showed a synechially angle closure in the right eye (upper photo) and left eye (lower photo).

3rd Global Ophthalmology and Eye Diseases Summit

was established. Nd: YAG Laser Peripheral Iridotomy (LPI) was done for both eyes and neither opened the angle nor controlled the IOP. Maximum topical medications were started and IOP became controlled. Given the age of the patient and disc cupping status, Trabeculectomy plus Mitomycin C was performed for the left and then the right eye. Over the next 4 months, IOP was controlled

without any medication bilaterally. To the best of our knowledge, this is the youngest reported case of isolated bilateral pseudoplateau iris with secondary angle closure glaucoma.

Conclusion: This case highlights the importance of a comprehensive eye exam for all preschool age groups for early diagnosis and treatment of any subclinical ophthalmic conditions.

“
**Profiling the early
 covert stage of the
 lacrimal gland in
 Sjögren syndrome
 susceptible mice**
 ”

Ammon B. Peck

College of Veterinary Medicine, University of Florida, USA

Sjögren's Syndrome (SS) is a human systemic autoimmune disease characterized clinically as the loss of normal lacrimal and salivary gland functions leading respectively to dry eye and dry mouth pathologies. Although a majority of SS studies in both humans and rodent models have long focused on pathophysiological events and the potential role of T lymphocytes in these events, recent studies have indicated that marginal zone B (MZB) lymphocytes are critical for both development and onset of SS disease. Although MZB cells are difficult to study in vivo and in vitro, we have carried out ex vivo investigations that use temporal global RNA transcriptomic analyses to profile early-stage cellular and molecular events in these exocrine glands of the C57BL/6.NOD-*Aec1Aec2* mouse, an extensively studied model that permits defining the underlying cellular and molecular basis for the onset and development of SS. The genome-wide transcriptomic analyses of extra-

orbital lacrimal glands indicate that genes and gene-sets temporally upregulated during early onset of disease define the Type1 interferon and Notch2/Nf-k β 14 signal transduction pathways, as well as identify chemokines, especially Cxcl13, and Rho-GTPases, including DOCK molecules, in the cellular migration of immune cells into the lacrimal glands. A comparison of the current results with our published salivary gland data obtained from similar studies carried out in C57BL/6.NOD-*Aec1Aec2* mice point to both similarities and differences in the etiopathogeneses underlying the autoimmune response within the two glands. Overall, this study identifies multiple molecular bioprocesses and signal transduction pathways activated in lacrimal glands at the initial preclinical covert pathogenic stage(s) of SS disease that will most likely impact future development of intervention therapies as the disease appears to vary significantly within the two exocrine glands.

“
**Intravital imaging reveals
 novel mechanisms
 of corneal lymphatic
 vessel remodeling
 and regulatory role of
 lymphatic endothelial
 cell primary cilia**
 ”

**D.M. Fink¹, D. Paulson¹, R. Harms¹, C. Ward¹, M. Latterell¹, H. Collazo¹, A. Majumder¹,
 and G.J. Pazour²**

¹South Dakota State University, USA

²University of Massachusetts Medical School, USA

In the healthy cornea, lymphatic vessels are restricted to the peripheral limbus. We employ a suture-based model of mouse corneal inflammation, resolution, and recurrent inflammation to study corneal lymphangiogenesis, lymphatic vessel regression, and recurrent lymphangiogenesis, respectively. The factors that regulate lymphangiogenesis in response to acute injury are well described. However, the signals that govern lymphatic vessel regression and recurrent lymphangiogenesis are poorly defined. We used the corneal model to identify novel regulatory mechanisms of lymphatic vessel patterning. We identified primary cilia on immortalized mouse and primary human lymphatic endothelial cells in vitro and on mouse lymphatic vessels in embryonic, postnatal, and adult tissues. Knock out of a protein required

for primary cilia assembly, IFT20, resulted in impaired lymphatic vessel patterning during development and exacerbated corneal lymphangiogenesis in mice. This suggests that signaling through primary cilia contributes to proper lymphatic vessel remodeling during development and disease. We used intravital microscopy to identify novel mechanisms of lymphatic vessel fragmentation and regression during wound healing, as well as fragment anastomosis and proliferation during recurrent inflammation. In summary, we have identified primary cilia as a novel hub for receipt of microenvironmental lymphangiogenesis cues by lymphatic endothelial cells and identified the cellular mechanisms encompassing regression and regrowth of corneal lymphatic vessels in response to inflammation.

“ Cascade Chaotic Neural Network (CCNN): A new model for image and vision processing

”

H. Abbasi¹ and M. Yaghoobi²

¹Department of Computer Engineering, Islamic Azad University, Iran

²Department of Control Engineering, Islamic Azad University, Iran

In recent years, studies on chaotic neural networks have been increased to construct a robust and flexible intelligent network resembling the human brain. To increase the chaotic performance and to reduce the time-complexity of conventional chaotic neural networks, this paper presents an innovative chaotic architecture called cascade chaotic neural network (CCNN). Cascade chaotic

system is inspired by cascade structures in electronic circuits. Cascade structure is based on a combination of two or more one-dimensional chaotic maps. This combination provides a new chaotic map that has more complicated behavior than its grain maps. The fusion of this structure into the network neurons makes the CCNN more capable of confronting nonlinear problems. In the proposed model,

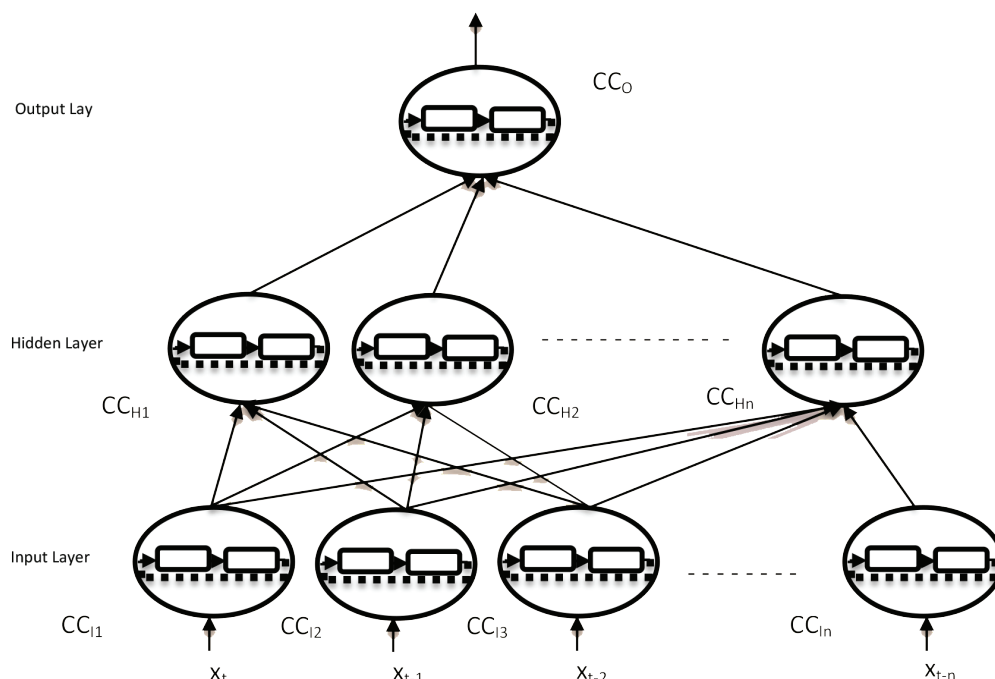


Fig.1 System architecture of CCNN for chaotic vision modelling

cascade chaotic activation function (CCAF) is introduced and applied. Using the CCAF with inherent chaotic features such as increasing variability, ergodicity, maximum entropy, and free saturation zones can be promising to solve or reduce learning problems in conventional AFs without increasing complexity. The complexity does not increase because no parameter is added to the system in use. The required chaos for neural network is generated by the Li oscillator, and then when using the

neural network, parameters are considered as constants. Chaotic behavior of the CCNN is investigated through bifurcation diagram. Also, modelling capability of the proposed model is verified through popular benchmark problems. Simulation and analysis demonstrate that in comparison with outstanding chaotic models, the CCNN provides more accurate and robust results in various conditions such as image enhancement and vision modelling.

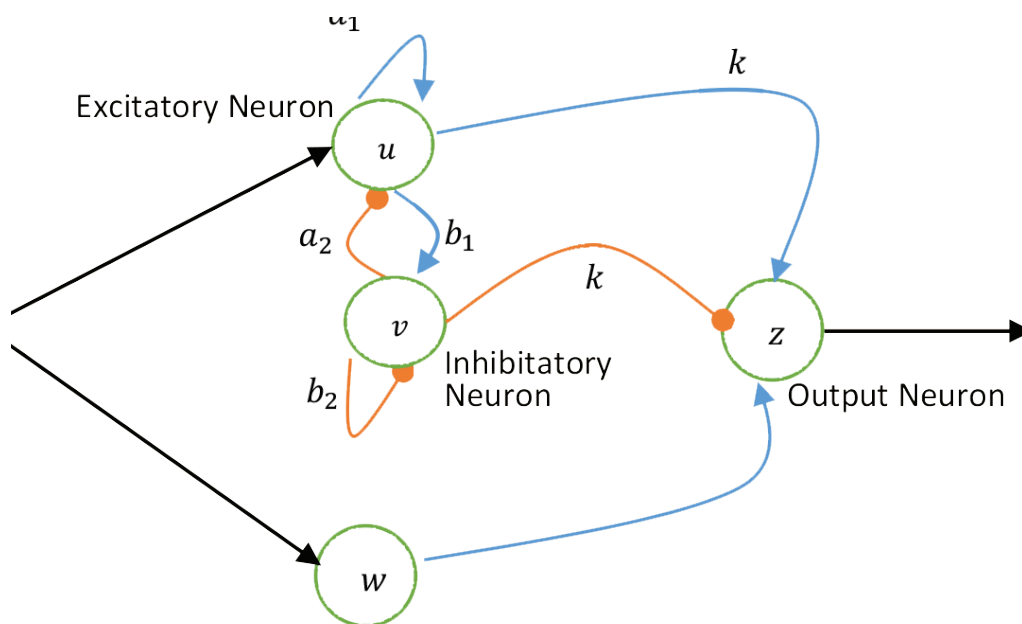


Fig. 2. Neuronal structure of LEE oscillator

“
**Evidence
 and possible
 mechanisms of
 probiotics in the
 management of
 type 1 diabetes
 mellitus**
 ”

Kodzovi S. Dovi and O. Bajinka
Central South University, P. R. China

Background: Type 1 Diabetes Mellitus (T1DM) is one of the most common chronic immune-mediated diseases. The prevalence is worldwide especially among children and young adults. The destruction of the pancreatic β -cells due to some abnormalities in the immune system characterizes T1DM. Considering the high burden of the disease and its impact on human health, researchers have made great efforts during the last decades; investigating the disease pathogenesis and discovering new strategies for its management. Fortunately, probiotics have been found as potential remedies for T1DM.

Objectives: This review aims to explore the potentialities of probiotics in managing T1DM and its complications.

Method: We explore the outcomes of human and animal studies carried out from 2016 to

2021 as evidence for the probiotic's effects on T1DM. We further searched and highlighted the possible mechanisms involved in these potentialities of probiotics.

Results: All the studies included in this review demonstrated the capacity of probiotics as therapeutic tools in the management of T1DM. Possible mechanisms of action of probiotics include; the modulation of the gut microbiota, the regulation of inflammation-related cytokines, the production of short chain fatty acids (SCFAs), and the regulation of Glucagon-Like Peptides 1 (GLP-1).

Conclusion: Probiotics can be used as possible therapeutic tools for the management of T1DM. However, we recommend that further studies especially human trials should be carried out to investigate the potentialities of probiotics.

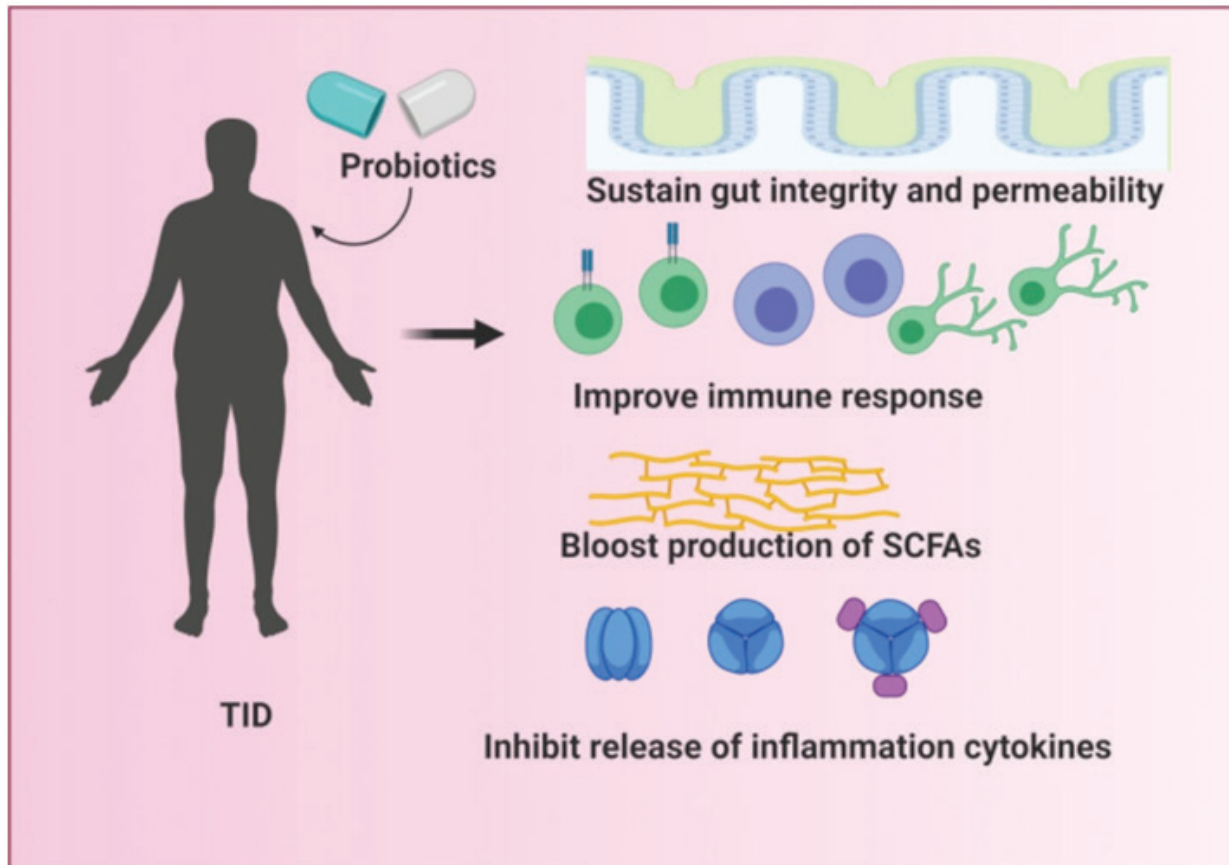


Figure caption: Probiotics mechanism of actions in the management of T1DM. Probiotics help improve the health conditions of T1DM patients by sustaining the integrity and permeability of the gut microbiota resulting in an improvement of the immune response. Probiotics are also able to boost the production of SCFAs. Furthermore, they are able to inhibit the release of inflammatory cytokines.



Factors affecting vision and visio- spatial intelligence (VSI) in sport: A review of the literature



Lourens Millard, Ina Shaw, Gerrit Jan Breukelman and Brandon Stewart Shaw
Department of Human Movement Science, University of Zululand, Republic of South Africa

Background: Sport has become increasingly competitive, prompting the need to determine, as far as possible, any likely performance advantage. While the focus of athletic research, testing and training focuses on the physiological and physical characteristics of the sport, visual abilities not only affect sport performance directly, but also affects the acquisition of motor skills. Vision, and visio-spatial intelligence (VSI), are a relatively new and underexplored area of athletic performance. As with physiological and physical parameters, a range of factors affect vision and VSI in sporting activities.

Objectives: This review of the literature is a first attempt to summarise and compile an

overview of the factors affecting vision and VSI in athletes, covering those previously connected with sport, as well as those hitherto not associated with athletic activities, but that could also play a part in sport performance.

Discussion: The evidence from this review suggests that while current research still tends to focus on single factors affecting vision and VSI, a large number of such factors have been identified that could affect vision and VSI. This offers new opportunities for researchers to investigate the effects of a combination of factors, and for conditioning and/or sports vision specialists to explore further possibilities for competitive advantage.

“Choroidal occlusive vasculopathy after intraarterial chemotherapy: MRI findings”

Roca-Cabau, M¹, Peralta Calvo², García Martínez F³, López Vázquez A⁴ and D’Anna O²

¹Retina and vitreous consultant, Hospital Universitario de Móstoles, Spain

²Paediatric ophthalmology professor, Hospital Universitario La Paz, Spain

³Radiologist consultant, Hospital Universitario La Paz, Spain

⁴Ophthalmology resident, Hospital Universitario La Paz, Spain

Purpose: To evaluate magnetic resonance imaging (MRI) findings in patients suffering choroidal occlusive vasculopathy (COV) after intra-arterial chemotherapy (IAC) for retinoblastoma.

Methods: A retrospective study of 37 eyes of 34 patients receiving IAQ between 2016 to 2021 as primary or secondary treatment for retinoblastoma was conducted. Twenty-two patients received systemic chemotherapy with carboplatin, vincristine and etoposide. The rest received IAC as primary treatment. The drugs administered were melphalan (3-4 mg), carboplatin (40mg) plus topotecan (20mg). The patients were examined under general anaesthesia every month to observe tumor regression and possible complications of the treatment. For the patients with COV an MRI was obtained to analyse the choroidal thickness and eye longitude.

Results: A COV was observed in 5 of the 37 eyes receiving IAC (13,51%), all of them with a complete sectorial choroidopathy not sparing the fovea (grade 2). In 4 of the 5 patients the thickness of the choroid was diminished and in three cases the size of the eye which presented COV was clearly smaller than the contralateral eye. The control of the tumor was archived in all 5 patients.

Conclusion: In our cases COV is generally associated with reduction of thinning of choroid and eye length in the MRI. A new classification maybe needed to correlate better with the severity of the complication affecting the fovea. Although early results generally are favorable to the use of IAC, longer follow up and scrupulous documentation of side effects will be necessary to know the true role of IAC for retinoblastoma.

“
**Exposure to urban
air pollution
particulate
matter and ocular
disorders**
”

Mojtaba Ehsanifar¹ and Banafsheh Kharrazi Ghadim²

¹Anatomical Sciences Research Center, Kashan University of Medical Sciences, Iran

²Nikookari Eye Hospital, Tabriz University of Medical Sciences, Iran

About 90% of the world's population is exposed to air pollutants beyond the limits of the World Health Organization (WHO) recommended. Due to regular contact of atmospheric air with the cornea, tear film, and conjunctiva, the pollutants present in the air have direct access to these ocular structures. Exposure to different parts of the eye to polluted air results in burning and redness of the eye, ocular disorders, and several other problems. Several studies have shown the drastic impact of air pollution on the eyes. In addition to these short-term effects,

air pollution can also affect eyesight. Recently studies have linked air pollution exposure with the risk of glaucoma. Based on these findings of inner retinal changes, the research suggests that PM_{2.5} may be an independent risk factor for glaucoma. The effects of air pollutants on the eyes are thought to be limited to the surface of the eye and simple eye irritation. While exposure to air pollution has a much greater impact on the eyes than we think. In this minireview, we investigated ocular disorders following exposure to air pollution particulate matter.



Spatial diversity in *Aspergillus niger* and yeast cultures in terms of starch saccharification and bioethanol production



N. Manzoor^{1,2}, S. Ullah², A. Iqbal³, M. Iqbal², Zulqarnain⁴ and A. Alam²

¹Department of Microbiology, Kohat University of Science and Technology, Pakistan

²Department of Agricultural Chemistry, The University of Agriculture, Pakistan

³Department of Agriculture, Abdul Wali Khan University, Pakistan

⁴Directorate of Soil and Plant Nutrition, Agricultural Research Institute, Pakistan

In this study, soil and corn samples of distinct areas were used to isolate strains of *A. niger* and yeast and variable colony counts per area were studied for starch saccharification and ethanol fermentation. Highest (57%) starch saccharification was from the *A. niger* isolated from the soil sample of Rabi, whereas Mardan Motorway Interchange was less productive in starch saccharification. The corn sample of Takhtbhai was highest (55%) in starch saccharification, in comparison to Malakhandher. Similarly, yeast strains from the soil samples of Jhandu and corn samples

of Jalala produced higher ethanol distillate (29 and 19 mL) compared to the yeast cultures isolated from other areas. Corn and soil samples of Malakandher and Jalala attained highest bioethanol recovery per 100 mL of distillate, respectively. Distinct strains of *A. niger* and yeast present in different areas showed great diversity in saccharification and fermentation, which might be due to variations in microbial strains and the environment around them. The best of *A. niger* and yeast strains could be used in bioethanol and other industries as a raw material.

“Influence of ceaseless pesticide application on the eyes”

Oluwatoyin Adenike Fabiyi

University of Ilorin, Nigeria

The spate of pest infestation of several crops has necessitated recurrent use of pesticides. Pesticides belong to organochlorines, carbamates and organophosphates. They are widely used by farmers and non-farmers alike. Systematic exposure to pesticides devoid of protective equipment leads to probable health threat. This improper practice exposes a number of people in the category of field workers, farmers, pesticide applicators and sundry others in agricultural and non-agricultural sector to danger. Incautious handling of pesticides without thorough hand washing after spraying exercise increases the likelihood of hand to eye contact. Ground workers are also prone to pesticide toxicity through aerial spraying over farms. The general populace is equally at risk in this circumstance. Agricultural workers are highly vulnerable to pesticide toxicity and the attendant ocular problems. Diverse exposure routes include inhalation, dermal contact, ocular exposure, direct ingestion and indirect ingestion through residue. Ocular toxicity of pesticides has been

widely reported, in some cases dose toxicity interaction has been established. The effect of pesticide toxicity is spotted in the optic nerve, cornea, retina, lens and conjunctiva. Typical presentation of pesticide toxicity includes itchiness, watery eyes, blurred vision and burning sensation. In some cases, the cornea may be injured, coupled with damage to the epithelium and visual acuity may decrease. Applicators of pesticides are confronted with retinopathy, retinal degeneration, while optico-autonomic peripheral neuropathy is reported in some cases. This condition on the retina develops in to retinal pigment degeneration, papilledema of optic disc and constriction of retinal vasculature. Primarily, it is pertinent to safe guard the eye from pesticide toxicity. Eye safety could be enhanced with utmost care at workplaces. recognition of populations with high-risk ocular toxicity and close monitoring of symptoms. A crucial element of public health and preventive medicine is protection of the eyes. It is paramount to stave off pesticide exposures in pursuance of public eye health.

“Glycopeptide drugs from endogenous hormones”

R. Polt², T. Falk¹, L. Madhavan¹, M.L. Heien², J.M. Streicher³, H.W. Morrison⁴, L. Szabò², R.K. Rowe⁵ and H.M. Mansour⁶

¹Dept. of Neurology, The University of Arizona, USA

²Dept. of Chemistry & Biochemistry, The University of Arizona, USA

³Dept. of Pharmacology, The University of Arizona, USA

⁴College of Nursing, The University of Arizona, USA

⁵Dept. of Integrative Physiology, University of Colorado, USA

⁶Center for Translational Science, Florida International University, USA

Endogenous neuropeptides and hormones are potent and selective agonists for GPCR receptors, and play important roles in inflammation, cell repair and healing. Unfortunately, these highly amphipathic peptides bind tightly to biological membranes and do not distribute throughout the body or cross cellular barriers, and are thus poor candidates as drugs. Our research has shown that it is possible to glycosylate these peptides to alter their membrane affinity, resulting in glycopeptides with enhanced PK/PD properties.

Two classes of glycopeptides have been explored, angiotensin1–7 agonists (PNA5) that bind to the Mas receptor, and PACAP/VIP agonists that bind to the PAC1 receptor. Both receptors offer unique opportunities for neuroprotection and treatments to intervene in the progression of neurodegenerative diseases. We have demonstrated that glycosylation of PACAP and other peptide hormones promotes penetration of the BBB and improves PK properties while retaining efficacy and potency

in the low nanomolar range at its target receptors. Furthermore, judicious structure-activity relationships (SAR) reveal key motifs that can be modulated to afford glycopeptides with diverse selectivity profiles. We have demonstrated that select PACAP glycopeptide analogues (2LS80MeI and 2LS98Lac) exert potent neuroprotective effects and anti-inflammatory activity in animal models of traumatic brain injury, stroke and in animal models for Parkinson’s disease. The smaller, more accessible PNA5 has been produced at kilo scale using good manufacturing processes (cGMP), and has been formulated for first-in-human IND-enabling studies directed toward the treatment of vascular dementia.

Results from animal disease models (mice and rats) will be presented. Since the close connection between the eye and central nervous system has been recognized for quite a while now, it seems likely that these drug candidates may be useful in the treatment of ocular neurodegenerative diseases.



“ Ocular manifestations of Syphilis ”

F. Sarra Hellal¹ and Boubekeur hafsa²

¹*Institute Mustapha Bacha hospital, Algeria*

²*Biochemistry department, University of M 'sila, Algeria*

Syphilis is a sexually transmitted disease associated with *Treponema pallidum* infection. which can cause systemic infection, this disease can occur through various clinical manifestations. The ophthalmologist should suggest the diagnosis in a patient with uveitis or optic neuropathy and with risky sexual behaviors and a state of immunodeficiency. In addition, posterior plaque chorioretinitis or necrotizing retinitis should investigate this etiology. Ocular involvement occurs mainly during the secondary and tertiary stages of the disease. Syphilis can affect any tissue in the eye. Uveitis is the

most common disease (1 to 5% of uveitis in tertiary centers) in the form of granulomatous or nongranulomatous anterior uveitis, posterior uveitis, panuveitis, or keratouveitis. Central nervous system involvement may be asymptomatic but is frequent, which justifies the systematic performance of a lumbar puncture for uveitis and/or optic neuropathy. The diagnostic confirmation is essentially serological. Parenteral treatment with penicillin G is the first-line treatment for ocular syphilis. Given the possibility of reinfection, follow-ups are required. The ocular prognosis is usually favorable after adequate antibiotic treatment.

“
Centration in
small incision
lenticule
extraction
”

Shengtao Liu

Eye and ENT Hospital, Fudan University, China

Small incision lenticule extraction (SMILE) is a new technique that exhibits excellent efficacy, safety and predictability for the correction of myopia and myopic astigmatism. However, one potential limitation of this technique is that the centration during femtosecond laser cutting might be subject

to the surgeon's experience and patient's cooperation. To achieve accurate centration in SMILE is the key to obtaining good postoperative visual outcomes. This article discusses the centration methods and the influencing factors in SMILE, so as to provide reference for clinical practice of SMILE.



Nanofibrous scaffolds with ex vivo cultured primary hRPE cells for transplantation into porcine eyes



T. Ardan¹, G. Petrovski^{4,5}, H. Studenovská², R. Nagymihály⁴, L. Lytvynchuk⁶, B. Mueller⁶, K. Stieger⁶, Z. Straňák⁷, L. Tichotová¹, Š. Popelka², Z. Ellederová¹, S. Drutovič¹, S. Rohiwal¹, M. Sedláčková³, J. Čížková¹, J. Juhásová¹ and J. Motlík¹

¹Institute of Animal Physiology and Genetics, Academy of Sciences of the Czech Republic, Czech Republic

²Institute of Macromolecular Chemistry, Academy of Sciences of the Czech Republic, Czech Republic

³Department of Histology and Embryology, Masaryk University, Czech Republic

⁴Department of Ophthalmology, Oslo University Hospital, Norway

⁵Institute of Clinical Medicine, University of Oslo, Norway

⁶Department of Ophthalmology, Justus-Liebig-University Giessen & Eye Clinic, University Hospital Giessen and Marburg GmbH, Germany

⁷Eye Clinic, University Hospital Kralovske Vinohrady, Czech Republic

Objective: The damaged retinal pigment epithelium (RPE) is a cause of many retinal degenerative diseases such as age-related macular degeneration (AMD). Replacement of damaged RPEs by transplantation of ex vivo cultured human primary RPEs (hRPEs) on polylactide nanofibrous membrane can serve as a perspective therapy for such incurable diseases.

Scope: This study aimed to investigate the possibility to culture ex vivo fully functional RPEs on nanofibrous scaffolds and to deliver them into the subretinal space using a newly developed delivery device.

Results: Primary cultures of hRPE showed high melanization. Immunocytochemical and biochemical characterization of the ex vivo

cultured hRPEs on nanofibrous scaffolds showed a reduction in the expression of common RPE markers, such as CRALBP, and RPE65, while the expression of ZO-1, PEDF, and other endothelial-to-mesenchymal transition (EMT) markers were elevated, compared to that of native RPE cells. Both electron microscopy techniques confirmed good confluency and a cuboidal morphology of the cultured hRPEs. Scaffolds with seeded hRPEs were successfully implanted into the subretinal space of porcine eyes. OCT and fundus camera examinations could localize the implant in the subretinal space and demonstrated a normal neuroretina in the place of the implant with healed retinotomy, without inflammatory reaction on the implant and in its surrounding.

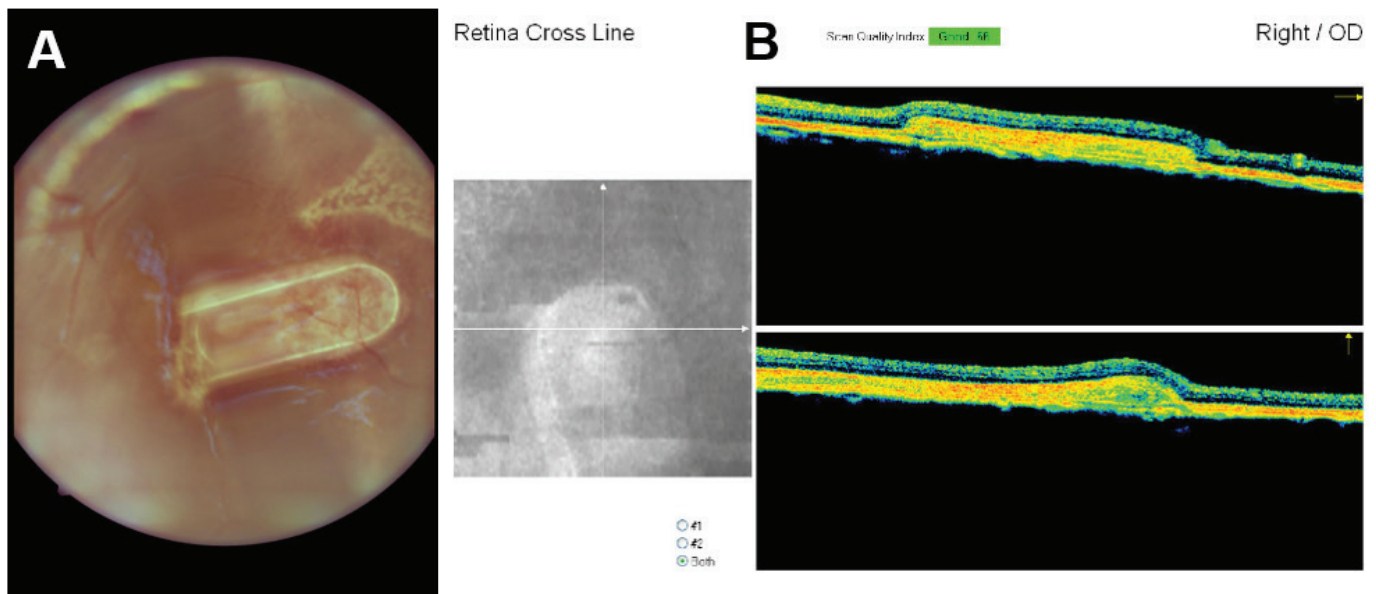


Figure: Fundus (A) and Optical Coherence Tomography (B) imaging of the implanted primary hRPEs on a nanofibrous carrier into minipigs.

Methods: The hRPEs were isolated from cadaver eye bulbs and were first cultured in clear polystyrene plates for 10-14 days, then transferred to polylactide nanofibrous membranes and cultured for an additional 3-4 weeks. Functional and morphological properties of the ex vivo cultured hRPEs included immunocytochemistry, real-time qPCR, and scanning- and transmission-electron microscopy. Scaffolds with confluent hRPEs were implanted into the right eye of five minipigs using 3-port pars plana vitrectomy and a newly designed implantation device. The xenogeneic transplantation was supported by immunosuppressive therapy with Tacrolimus.

At 3 weeks following transplantation, non-invasive examinations of the implanted retina were performed using OCT and fundus camera.

Conclusion: Morphological and gene expression characterization of hRPEs confirmed, that the nanofibrous membrane supported the survival of the cells, even after being loaded into the subretinal space. Gene expression analysis revealed a reduction of RPE-specific genes, with the simultaneous upregulation of genes related to EMT, however, the correct placing of implants into the subretinal space confirmed the safety of the employed surgical technique and the functionality of the delivery device.

“
**Teleretinal screening
 for detection of diabetic
 retinopathy and age-
 related macular
 degeneration: A diagnostic
 accuracy meta-analysis**
 ”

Tina Felfeli^{2,3,4}, Parsa Mehraban Far¹, Felicia Tai², Adeteju Ogunbameru^{3,4}, Petros Pechlivanoglou^{4,5}, Beate Sander^{3,4}, David T Wong^{2,6} and Michael H Brent^{2,7}

¹Department of Ophthalmology, Queen's University, Canada

²Department of Ophthalmology and Vision Sciences, University of Toronto, Canada

³Toronto Health Economics and Technology Assessment (THETA) Collaborative, University Health Network, Canada

⁴Institute of Health Policy, Management and Evaluation, University of Toronto, Canada

⁵The Hospital for Sick Children, University of Toronto, Canada

⁶Department of Ophthalmology, St. Michael's Hospital, Canada

⁷Donald K Johnson Eye Institute, University Health Network, Canada

Objective: To perform a diagnostic test meta-analysis evaluating the accuracy of teleretinal screening performed by human graders for the detection of diabetic retinopathy (DR) and age-related macular degeneration (AMD).

Methods: We adhered to the Preferred Reporting Items for a Systematic Review and Meta-analysis of Diagnostic Test Accuracy Studies (PRISMA-DTA). A detailed search of OVID MEDLINE, EMBASE and Cochrane CENTRAL was performed encompassing January 2010 to July 2021. Referrable DR was defined as disease state equal to in severity or more severe than moderate non-proliferative diabetic retinopathy OR the presence of diabetic macular edema. Face-to-face examination was chosen as the reference standard of choice

given its acceptance as an accurate diagnostic modality for both DR and AMD. Meta-analysis was performed using a bivariate random effects model and QUADAS-2 was applied to assess the quality of included studies.

Results: A total of 28 articles met the inclusion criteria. Meta-analysis of 13 studies (n=7207) for detection of any DR achieved a sensitivity of 0.91 (95% CI: 0.82 to 0.96) and specificity of 0.88 (0.74 to 0.95). Meta-analysis for referrable DR based on 10 studies (n=6373) achieved a sensitivity of 0.88 (0.81 to 0.93) and specificity of 0.86 (0.79 to 0.90). Teleretinal screening for detection of any AMD based on 3 studies (n=697) achieved a sensitivity of 0.71 (0.49 to 0.86) and specificity of 0.88 (0.85 to 0.90).

3rd Global Ophthalmology and Eye Diseases Summit

Conclusion: Teleretinal Screening achieved promising sensitivity and specificity for the detection of DR. Teleretinal Screening for AMD detection is promising, however, data from more studies is required to provide a robust

assessment. The present study evaluated teleretinal screening performed by human graders, therefore, the role of machine-learning in image classification remains to be explored in another meta-analysis.



Interactions between diabetic retinal microvasculopathy and neuronal degeneration assessed by swept-source OCT and OCT angiography



Xinyuan Zhang and Bingjie Qiu

Department of Ophthalmology, Beijing Tongren Eye Center, China

Objective: To provide clinical evidence of the associations between retinal neuronal degeneration and microvasculopathy in diabetic retinopathy (DR).

Methods: This cross-sectional study included 77 patients (113 eyes) with type 2 diabetes mellitus (DM), refraction error between -3.0 and +3.0 D. The eyes were assigned into DM (without DR), non-proliferative DR (NPDR), and proliferative DR (PDR) groups. Age-, sex-, and refractive error-matched normal subjects were enrolled as controls. The Early Treatment Diabetic Retinopathy Study mean thickness of the retina (mtTR), the relative mean thickness of the retinal nerve fiber (rmtRNFL, rmtRNFL/rmtTR) layer, ganglion cell (rmtGCL) layer, ganglion cell complex (rmtGCC) layer, and the foveal avascular zone (FAZ) were assessed by swept source optical coherence tomography and OCT angiography. Group comparison and Spearman partial correlation coefficient analysis were applied to evaluate the correlation between these morphological parameters and systemic factors.

Results: The rmtRNFL significantly increased with the DR severity and duration of diabetes. Statistical differences were detected in the rmtRNFL thickness between the normal, DM,

NPDR, and PDR groups ($P < 0.0001$, $P_{\text{Normal/ NPDR}} < 0.0001$, $P_{\text{Normal/=PDR}} = < 0.0001$). The rmtRNFL was significantly increased in the DM groups with a disease course of 1–10, 11–19, and ≥ 20 years than that in the normal control group ($P_{\text{Normal vs.1-10yrs}} = 0.031$, $P_{\text{Normal vs.11-19yrs}} < 0.0001$, $P_{\text{Normal vs.}\geq 20\text{yrs}} = P < 0.0001$).

Also, the rmtGCL decreased with the DR severity ($P = 0.003$, $PPDR \text{ vs. Normal} = 0.013$, $P_{\text{PDR vs.DM}} < 0.0001$, $PPDR \text{ vs. NPDR} = 0.002$). The FAZ area significantly increased with the DR severity ($P < 0.0001$; $PPDR \text{ vs.DM} = 0.0001$, $PPDR \text{ vs. NPDR} < 0.0001$; $P_{\text{Normal vs.PDR}} < 0.0001$). rmtRNFL and FAZ area were significantly correlated with the severity of DR after controlling the age, sex, and duration of diabetes, and hypertension ($P_{\text{rmtRNFL}} < 0.0001$, $P_{\text{FAZ}} = 0.001$), while rmtGCL was negatively correlated with FAZ area ($P < 0.0001$).

Conclusions: The degree of rmtRNFL and FAZ area enlargement is correlated with the severity of DR. rmtRNFL is a stronger predictor of the progression of DR than FAZ area. The ganglion cell body loss is highly correlated with FAZ area enlargement in the progression of DR.

Disclosure of Interest: None Declared



Quantitative visualization of a round under expanded hydrogen jet using Background Oriented Schlieren (BOS) technique



Yang Miao^{1,2}, Chenghao Jia¹, Luqiao Yao¹, Xi Chen¹, Ningzheng Li³ and Yu Shu¹

¹Faculty of Materials and Manufacturing, Beijing University of Technology, China

²Beijing Key Laboratory of Advanced Manufacturing Technology, Beijing University of Technology, China

³School of Chemical Sciences, University of Chinese Academy of Sciences, China

Nowadays, climate change and the transformation of economic development model have attracted more and more attention from countries around the world. As a major global economy and the most active international actor in addressing climate change, The European Union considers hydrogen as not only a technique to achieve "carbon neutrality", but also an important way to achieve economic structural transformation and inject vitality during the post-pandemic era. However, characteristics of hydrogen are fast flame spread rate, widely range of combustion rate, low ignition energy and transparent. Leakage in any circumstances by using hydrogen energy may result in disaster. Therefore, it is necessary to study the visualization of hydrogen leakage.

According to Gladstone-Dale law, the relationship between refractive index and density of leakage jet can be expressed as follows:

$$n-1=k\rho, \quad (1)$$

where n is the refractive index, k is Gladstone-Dale constant, ρ is density. Therefore, the density can be obtained by measuring the

refractive index of leakage jet. BOS technique can obtain the jet's density by measuring the refractive index of leakage jet. The schematic diagram of BOS technology is shown in Fig. 1

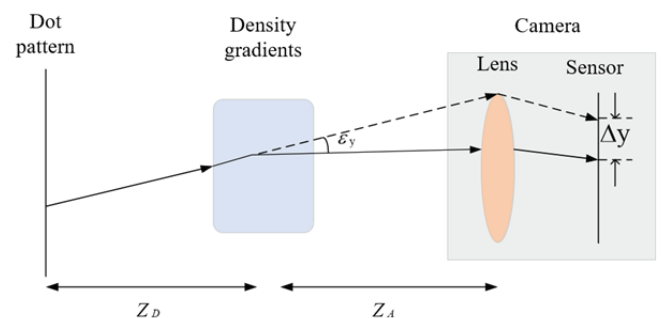


Fig. 1 Basic principle of BOS

There is a background panel with a specific pattern on far left in Fig. 1. On the far right is a CCD camera for taking images. Leakage jet is in the middle of fig.1. The dotted line between the background plate and the CCD camera represents light without interaction of leakage jet. On the other hand, solid lines represent light with interaction of leakage jet. Z_A is the distance between the CCD camera

and the leakage jet. Z_D is the distance between the leakage jet and the background plate. ε_y is the deflection angle of the light ray in the figure. The displacement of light in the y direction with interaction of leakage jet is Δy . The focal length of the CCD camera lens is f. n_0 is the refractive index of circumstance air. n is the refractive index of leakage jet. Δy can be expressed as follows:

$$\Delta y = \left(\frac{Z_D}{Z_D + Z_A + f} \right) \frac{f}{n_0} \int \frac{\delta n}{\delta y} dz \quad (2)$$

Therefore, we can obtain the displacement of dots in background panel image by our technique. Then the refractive index distribution of leakage jet can be obtained. According to equation (1), the density distribution of leakage jet can be calculated as well.

Because hydrogen is very easy to burn and explosive, leakage characteristics of helium are similar to hydrogen. For that reason, in this experiment, helium replaces hydrogen as the leakage source to produce a round underexpanded hydrogen jet. Firstly, the particle pattern is placed behind leakage jet as the background. Light from particle pattern through leakage jet is obtained by CCD camera. The displacement of each particles are calculated by using correlation algorithm. The density distribution and refractive index distribution of leakage jet are analyzed according to the particle displacement, respectively.

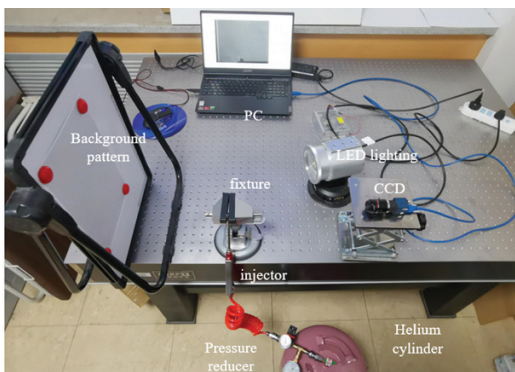


Fig. 2 BOS experimental device diagram

In our experiment, mass flow rate is 3 g/s, temperature is about 290 K, and froude number is about $Fr=3600$. It means that buoyancy effect is not considered. Over 800 images were obtained by the camera with resolution of 4368×2912 pixels during 16 times. Due to the change of refractive index on optical path, each particles is offset in CCD camera. Each images with leakage jet and image without leakage jet are combined by using correlation algorithm. Fig. 3 shows that series of images with 4mm nozzle at outlet pressure of 0.2Mpa, 0.6Mpa and 1Mpa, respectively are obtained by using BOS technique.

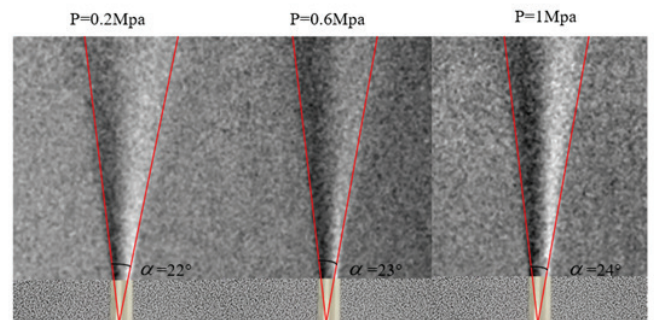


Fig. 3 BOS image of leakage jet (pressure is 0.2MPa, 0.6MPa and 1MPa respectively)

Because the jet expansion and shear layer are mixed with the radial flow velocity air. Radial concentration and velocity of leakage jet decrease along radial profile from centerline to edges of the jet. The Concentration and flow rate of leakage jet are normally distributed, which can be well described by Gaussian function:

$$C(x) = C_0 A \frac{d_0}{x+x_0} \left(\frac{\rho_{He}}{\rho_a} \right)^{1/2} \quad (3)$$

$$U(x) = u_0 A \frac{d_0}{x+x_0} \left(\frac{\rho_{He}}{\rho_a} \right)^{1/2} \quad (4)$$

$$C_{He}(r) = \frac{A_0}{\sigma \sqrt{2\pi}} \exp\left(-\frac{(r-u)^2}{2\sigma^2}\right) \quad (5)$$

$$U(r) = \frac{B_0}{\sigma \sqrt{2\pi}} \exp\left(-\frac{(r-u)^2}{2\sigma^2}\right), \quad (6)$$

3rd Global Ophthalmology and Eye Diseases Summit

where A and B are empirical constants, C_0 and u_0 is the initial concentration and flow rate, d_0 is the original nozzle diameter, x_0 is the virtual origin displacement, ρ_{He} is the density of leakage jet, air in the storage tank ρ_a is the density of ambient air, and r is the distance from the jet axis, $A_0/(\sigma(2\pi)^{1/2})=C(x)_{max}$

and $B_0/(\sigma(2\pi)^{1/2})=U(x)_{max}$ are the maximum concentration and flow rate of leakage jet at the distance x. Knowing all parameters of the equations (3)-(6), we can predict concentration and velocity of leakage jet.

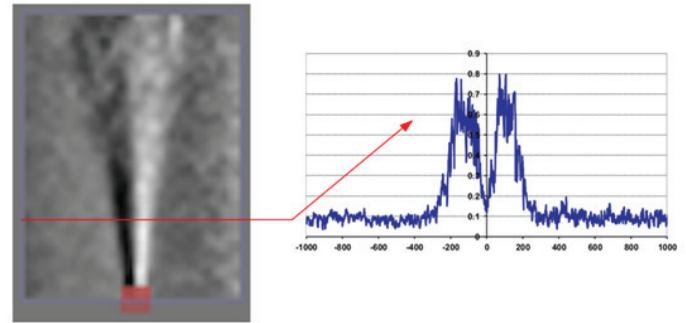


Fig. 4 BOS image of leakage jet (left) and the displacement data in radial direction(right).

We can obtain data from curve (Fig. 4). We're processing these data to find a quantitative link between image displacement and concentration or velocity gradient.



Diagnostic information profiling and evaluation of causative fungi of fungal keratitis using high-throughput internal transcribed spacer sequencing



Zhichao Ren^{1,2}, Qing Liu^{2,3}, Yuqian Wang², Yanling Dong² and Yusen Huang²

¹*School of Medicine and Life Sciences, University of Jinan-Shandong, China*

²*State Key Laboratory Cultivation Base, Shandong Provincial Key Laboratory of Ophthalmology, Shandong Eye Institute, Shandong First Medical University & Shandong Academy of Medical Sciences, China*

Early and accurate diagnosis is essential for the targeted management of fungal keratitis (FK), which is one of the major blinding eye diseases worldwide. To elucidate the diagnostic information of high-throughput internal transcribed spacer (ITS) sequencing for identifying causative fungi of FK, 38 patients who were highly suspected of having FK were included in this research. In vivo confocal microscopy, potassium hydroxide smear, and fungal culture were performed to diagnose FK. Culture and ITS sequencing were used to identify causative fungi. We hypothesized that the dominant genus was the result of pathogen identification by ITS sequencing. Thirty-five

patients were eventually diagnosed with FK, with fungal pathogens found by confocal microscopy in 27 patients (77.14%), by smear examination in 27 patients (77.14%), by culture in 25 patients (71.43%), and by ITS sequencing in 26 patients (74.29%). Eight causative fungal genera were determined by ITS sequencing, while five causative fungal genera were identified based on the morphology of the cultured pathogens. The results of ITS sequencing and culture were coincident in 10 patients with FK (28.57%). It is concluded that ITS sequencing, to some extent, challenged fungal culture and might be an optional complement in identifying fungal pathogens in corneas.



C1q/TNF-Related protein 3 prevents diabetic retinopathy via ampk- dependent stabilization of blood–retinal barrier tight junctions



Zheyi Yan^{1,2}, Chunfang Wang^{1,2}, Zhijun Meng¹ and Lu Gan¹

¹Department of Emergency Medicine, Thomas Jefferson University, USA

²Department of Ophthalmology, First Hospital of Shanxi Medical University, China

Background: The impairment of the inner blood–retinal barrier (iBRB) increases the pathological development of diabetic retinopathy (DR), a severe complication in diabetic patients. Identifying approaches to preserving iBRB integrity and function is a significant challenge in DR. C1q/tumor necrosis factor-related protein-3 (CTRP3) is a newly discovered adipokine and a vital biomarker, predicting DR severity. We sought to determine whether and how CTRP3 affects the pathological development of non-proliferative diabetic retinopathy (NPDR).

Methods: To clarify the pathophysiologic progress of the blood–retinal barrier in NPDR and explore its potential mechanism, a mouse Type 2 diabetic model of diabetic retinopathy was used. The capillary leakage was assessed by confocal microscope with fluorescent-labeled protein in vivo. Furthermore, the effect of CTRP3 on the inner blood–retinal barrier

(iBRB) and its molecular mechanism was clarified.

Results: The results demonstrated that CTRP3 protects iBRB integrity and resists the vascular permeability induced by DR. Mechanistically, the administration of CTRP3 activates the AMPK signaling pathway and enhances the expression of Occludin and Claudin-5 (tight junction protein) in vivo and in vitro. Meanwhile, CTRP3 improves the injury of human retinal endothelial cells (HRMECs) induced by high glucose/high lipids (HG/HL), and its protective effects are AMPK-dependent.

Conclusions: In summary, we report, for the first time, that CTRP3 prevents diabetes-induced retinal vascular permeability via stabilizing the tight junctions of the iBRB and through the AMPK-dependent Occludin/Claudin-5 signaling pathway, thus critically affecting the development of NPDR.



About us

A confluence of Erudite and Knowledge-Seeker

Peers Alley Media

A global consortium of the scientific fraternity, scholars, educationists, industry leaders and entrepreneurs to collaborate, share ideas and knowledge to resolve challenges across medicine, science, technology and business

Our Vision

"We aim to bring the research and innovations happening across the parts of the globe to facilitate interaction, knowledge sharing and exchange. We also aim to inspire university professors, students, researchers, clinicians and entrepreneurs from across the disciplines including but not limited to clinical, medical, business, technology, healthcare and pharmaceutical fields. Our dream is to bring advancements in the Science and Technology to the mankind through our scientific gatherings and deliberations. We believe in introducing novel methods and innovative techniques in science, business and technology to provide understanding on the developments".

Our Mission

How do we serve our target groups in the scientific & business community?

- We bring the untold research accessible for many.
- Our events meet the research needs of the target groups across the academia, industry, corporates, the government, non-government agencies and public bodies.
- We Engage. Enlighten. Empower people deprived of information.
- We connect the international giants towards finding simple solutions to the complex medical and healthcare challenges of the globe.
- We unveil the unlimited research opportunities to the sections of population that is away from the developments in science and technology.
- We encourage Young and emerging researchers and scholars.
- We extend continuous education credits to boost the career and academic progress.
- We encourage start-ups in science, technology and business for the social and economic empowerment of the enthusiastic entrepreneurs.

Peers Alley Media

1126 59 Ave East, V5X 1Y9, Vancouver BC, Canada

Ph : +1-778-766-2134 / Contact us: contact@peersalley.com

INDEX

Speaker	Pg No.
Ajakwe Simeon Okechukwu	15
Brandon Lucke-Wold	34
Catarina Seidi	37
Christian Garcia	59
Christopher Ifeanyi Ibenegbu	26
D. Permatasari	16
Dhyana Sharma	29
Dmitri Alekseevsky	50
Haroon Malak	35
Itay Nitzan	61
Lida Asgharian	49
M. Živković	52
Madhurima Roy	46
Magdalena Jotzo	31
Meeta Tyagi	11
Mohammed Abdu Seid	44
Mohammed Abdu Seid	54
Mohey A.E. Hulail	20

Speaker	Pg No.
Murat Okutucu	24
Murat Okutucu	18
MY Zhang	48
N. Amutha Prabha	43
N. Shakarchy-Kaminsky	57
O.Terkaouchi	23
Pragya Ahuja	22
Rozhan Khezri	27
S. Mastronikolis	9
Samira LAFRAXO	17
Suwarna Suman	41
Xinyue Li	13
Y. Shames	32
Yan Hua Wang	40
Yohannes Tewolde Kidane	42
Zaira Fernanda Martinho Nicolau	39
Zineb Boukhal Zerouali	47



NOVEL OPHTHALMOLOGY 2022

**BOOKMARK
YOUR DATES**

**4th GLOBAL
OPHTHALMOLOGY AND
EYE DISEASES SUMMIT**

September 12-13, 2023 | London, UK

<https://novel-ophthalmology.peersalleyconferences.com/>